Approach to Pediatric Arthritis

Dr. Jessica Bhullar
PGY-3 Pediatric Resident, CHEO

February 3rd, 2017 - Telehealth Rounds

Supervisor:
Dr. Watanabe Duffy

Objectives

- Recognize inflammatory versus mechanical joint pain
- Identify red flags on history and examination
- Understand the MSK physical examination pGALS (pediatric Gait Arms Legs Spine) screening tool
- Review a differential for arthritis
- Discuss an approach to investigations for arthritis

Presentation Outline

- Our case
- Definitions
- Approach to history
- Approach to physical examination
- Differential for pediatric arthritis
- Approach to investigations
- Next steps
- Take home points

Case: 9 year old ♂ with joint pain and swelling

- States both his wrists hurt
- Hasn't been able to put on his watch for two months
- Went to walk-in clinic three weeks ago → x ray
- Told there isn't anything broken but it's probably sprained and will get better with time
- But it still hurts and you see him in clinic today

Arthritis Defined

= Inflamed joint

- Joint with swelling or effusion

OR

- Minimum two of:
  - Joint line tenderness
  - Pain on motion (stress pain)
  - Limited range of motion

Areas of Joint Inflammation

Achilles enthesitis and ankle effusion

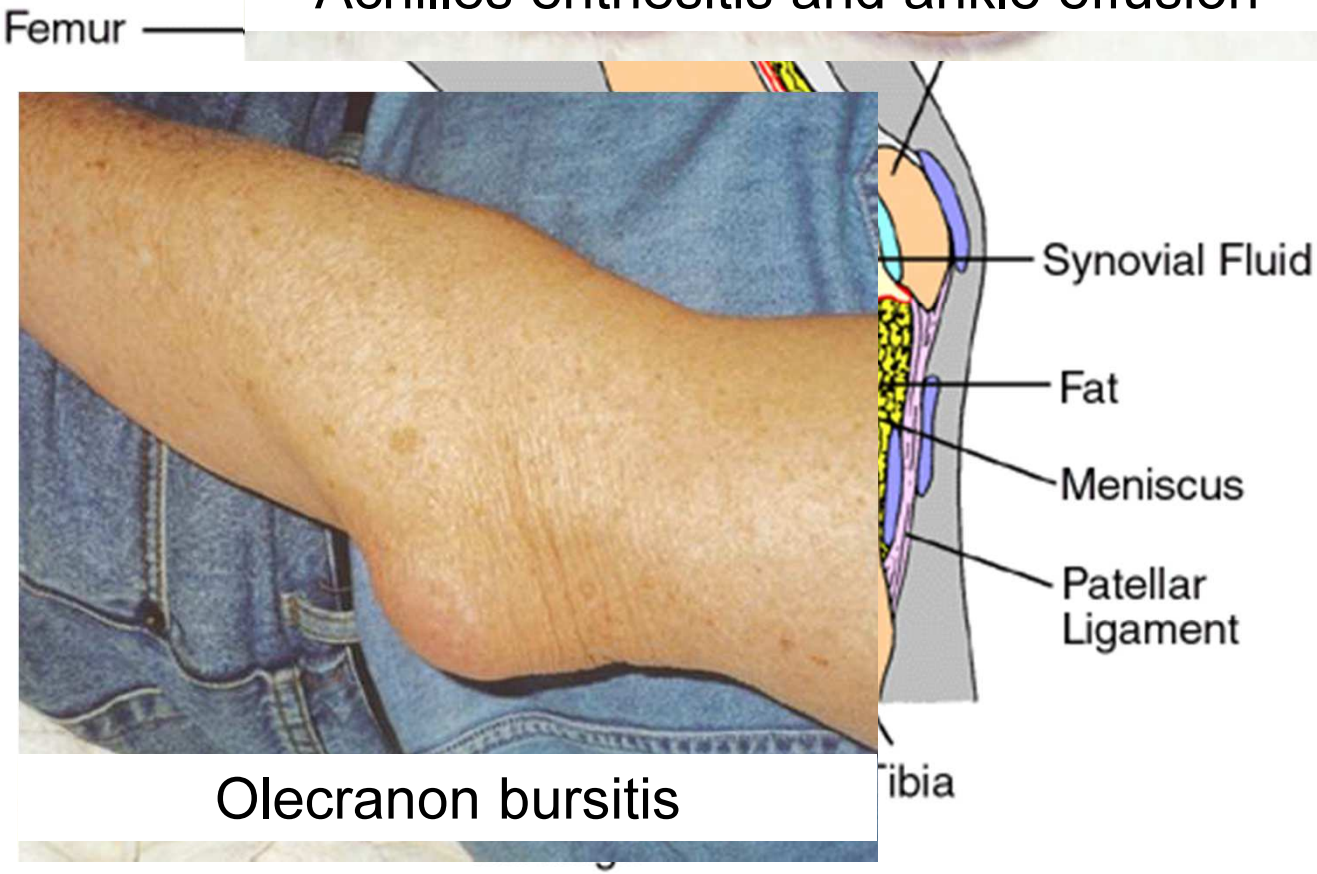

Olecranon bursitis

Images: http://www.chw.org/medical-care/rheumatology/conditions/anatomy-of-a-joint/; uptodate.com

Number of Joints

- **MONO**arthritis: SINGLE joint
- **OLIGO**arthritis: FOUR joints or fewer
- **POLY**arthritis: FIVE joints or more

PEARL: High Yield Question

Which feature(s) help differentiate inflammatory versus mechanical pain?

A. Morning stiffness

B. Change with activity

C. Swelling

D. All of the above

PEARL: High Yield Question

Which feature(s) help differentiate inflammatory versus mechanical pain?

Inflammatory	Mechanical
Persistent morning stiffness	Absent or mild, transient morning stiffness
Pain better with activity	Pain worse with activity
Warm, tender, swollen joints	Tender with minimal swelling

A. Morning stiffnes

B. Change with ac

C. Swelling

D. All of the above

Approach to History: HPI

- Characterize the pain +/- swelling
- Fever
- Recent infections
- Recent trauma
- Constitutional symptoms
- Associated symptoms
- Impact/functional limitations

PEARL: RED FLAGS

- Unwell child (constitutional symptoms)
  - Fever, weight loss, weakness, malaise
- Bone or night pain
- Regression of developmental milestones
- Significant functional disability
  - Not ambulating
  - Missing school or activities
- Neurological symptoms

Approach to History: Review of Systems

- <u>JIA related uveitis is often asymptomatic</u>
- Eye pain
- Erythema
- Visual Loss

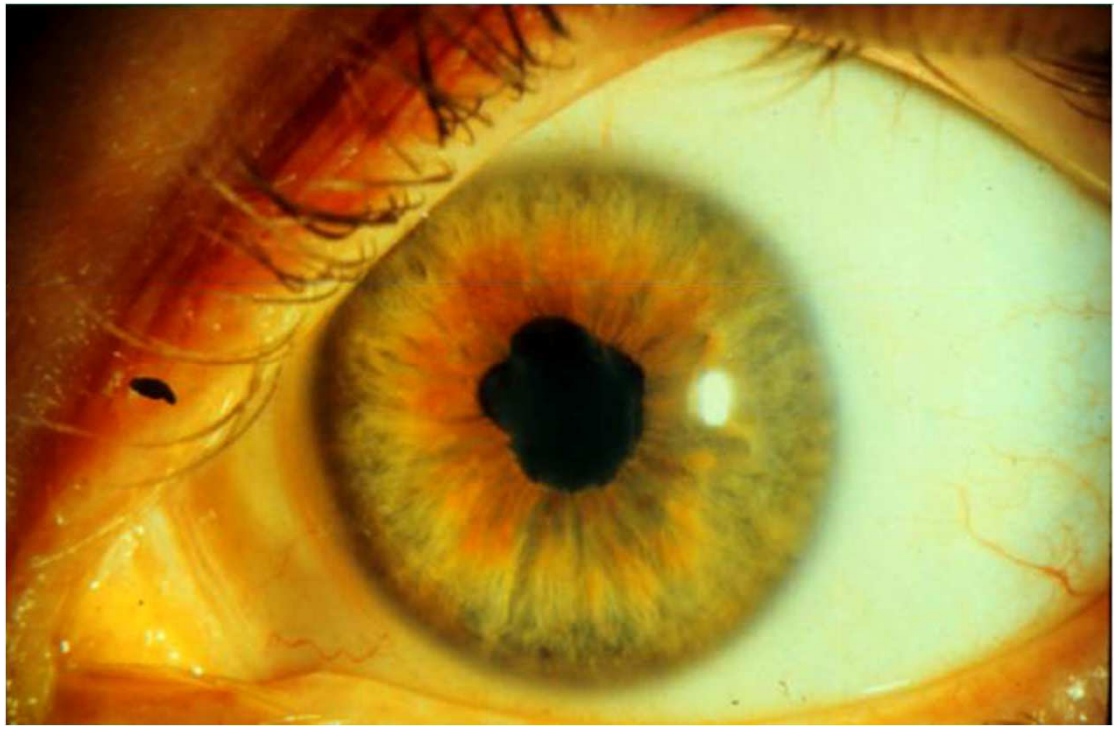

Uptodate.com

Approach to History: Review of Systems

- Don't forget GI
- Nausea
- Dyspepsia
- Vomiting
- Diarrhea
- Bloody Stools

Approach to History

PEARL: Review of Rashes

- Malar
- Psoriasis
- Salmon-Coloured Evanescent
- And Others…

Google Images, Peds in Review, Uptodate.com

Approach to History: Don’t Forget the Nails!

- Pitting

Uptodate.com

CHEO

Approach to History:

Don't Forget Sexual History!

**when appropriate*

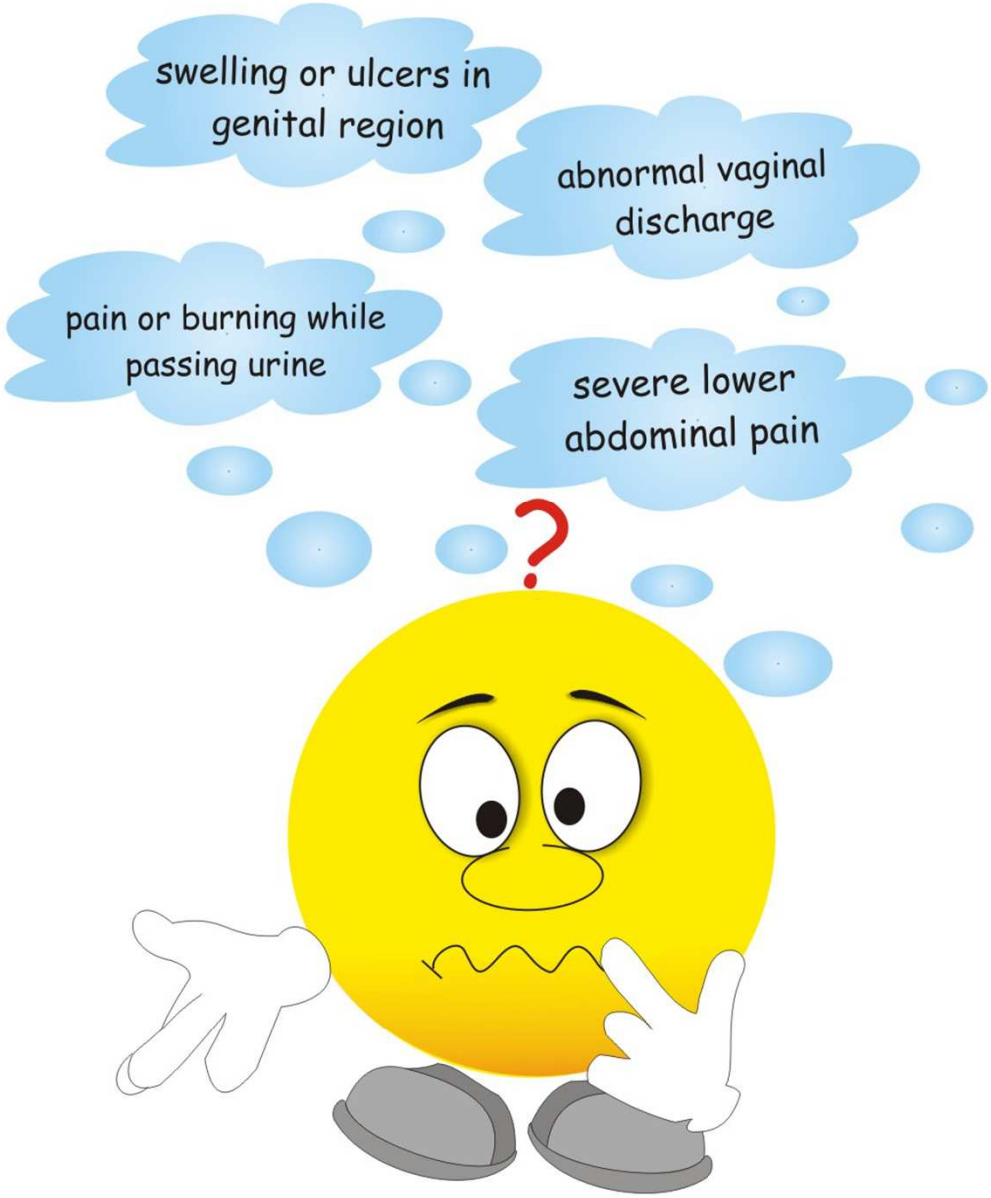

FACING ANY OF THESE ?

SEEK HELP AT THE NEAREST GOVERNMENT HEALTH CENTRE

Developed at National Institute for Research in Reproductive Health (ICMR), Mumbai

Approach to History: PMH

- History of inflammatory and AI conditions:
  - psoriasis
  - T1DM, Celiac disease
- GI: IBD

Approach to History: Family History

- Arthritis
- Autoimmune related disorders

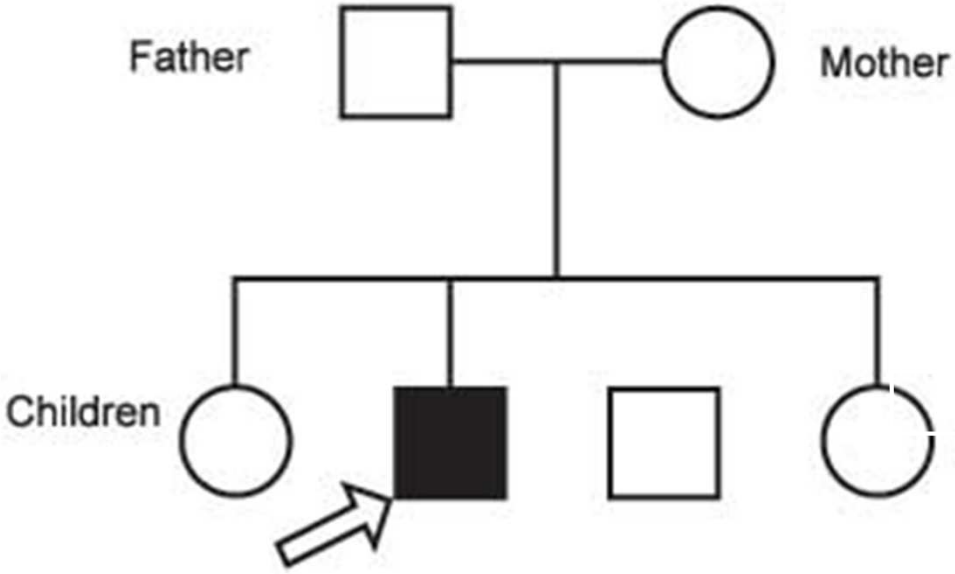

Approach to History: Social History

- Home
- Family unit
- Daycare or school
- Medical coverage



Vector Cartoon

Physical Examination

- Assess general health
- Complete examination
- All joints should be examined
- MSK Screening Exam: pGALS

pGALS (pediatric Gait Arms Legs Spine)

- Evidence-based simple and quick MSK screening assessment tool for school aged children
- Meant for non-specialist
- Well accepted by patient and families
- Validated with excellent sensitivity and specificity (97-100%) to identify MSK abnormalities
- Usually completed in ~ 2 minutes

PEARL: pGALS Video

http://www.arthritisresearchuk.org/health-professionals-and-students/video-resources/pgals/pgals-summary.aspx

Case: What Did We Find

- Afebrile
- No recent infections
- No constitutional symptoms

Differential for Arthritis

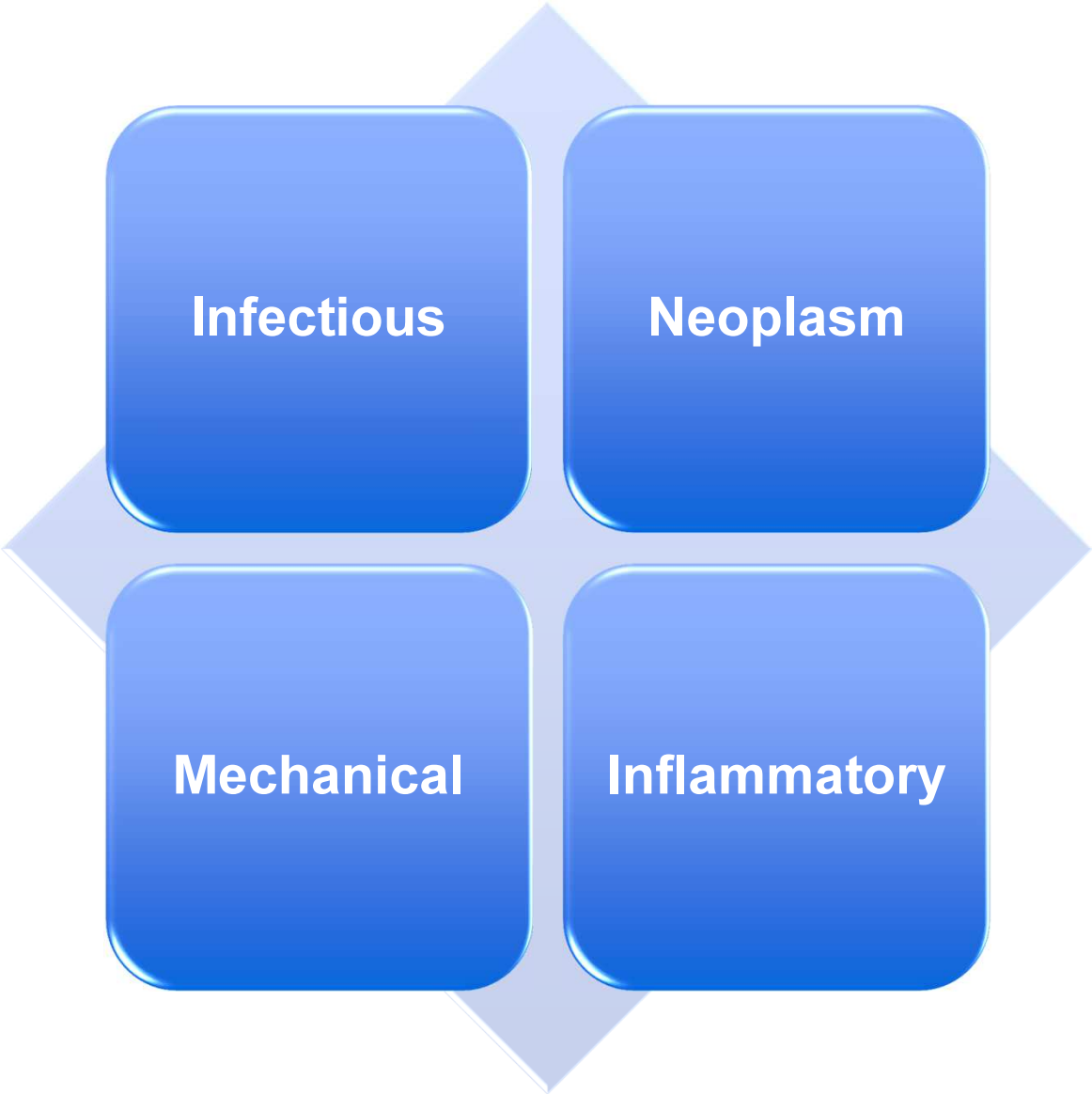

Differential for Arthritis: Infectious

RED, HOT, IMMOBILE JOINT:

think septic joint or osteomyelitis

- SEVERE pain
- Difficulty weight bearing
- Fever
- Recent infection
- Rashes

Differential for Arthritis: Neoplasm

- May have SEVERE pain
  - Disproportionate pain
  - Peri-articular pain
- <u>Bony pain</u>
- <u>Night pain</u>
- <u>Constitutional symptoms</u>

Differential for Arthritis: Mechanical

- History of TRAUMA

Inflammatory	Mechanical
Persistent morning stiffness	Absent or mild, transient morning stiffness
Pain better with activity	Pain worse with activity
Warm, tender, swollen joints	Tender with minimal swelling

Differential for Arthritis: Autoimmune

Arthritis can be a manifestation of connective tissue diseases.

- *Note: Juvenile idiopathic arthritis (JIA)*
  - Persistent minimum 6 week arthritis
  - Diagnosis of exclusion
  - Clinical diagnosis

Differential for Arthritis

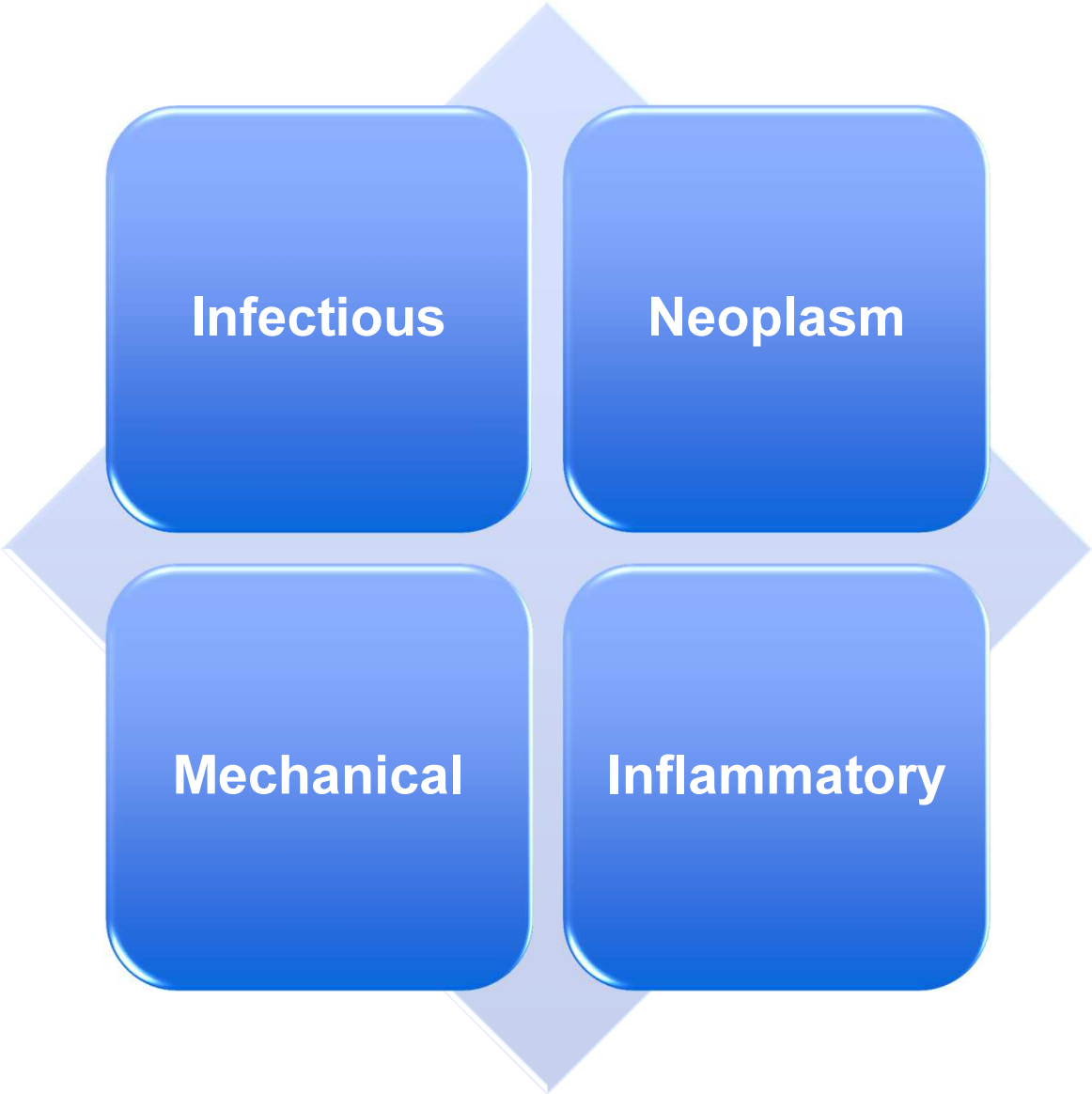

What is your impression?

Case: What Are Your Initial Orders?

- ❑ CBC + diff
- ❑ ESR, CRP
- ❑ ANA
- ❑ ds-DNA
- ❑ LFTs
- ❑ LDH
- ❑ Uric Acid
- ❑ Electrolytes
- ❑ Cr, BUN
- ❑ Viral Serology
- ❑ Blood Culture
- ❑ Urinalysis
- ❑ Urine Gonorrhea
- ❑ XR
- ❑ ASOT and Throat Swab
- ❑ US
- ❑ MRI
- ❑ Arthrocentesis
- ❑ Ophtho Referral
- ❑ Rheumatology Referral

Case: What Are Your Initial Orders?

- ❑ **CBC + diff**
- ❑ **ESR, CRP**
- ❑ **ANA**
- ❑ ds-DNA
- ❑ **LFTs**
- ❑ **LDH**
- ❑ **Uric Acid**
- ❑ **Electrolytes**
- ❑ **Cr, BUN**
- ❑ Viral Serology
- ❑ Blood Culture
- ❑ **Urinalysis**
- ❑ Urine Gonorrhea
- ❑ **XR**
- ❑ ASOT and Throat Swab
- ❑ US
- ❑ MRI
- ❑ Arthrocentesis
- ❑ Ophtho Referral
- ❑ Rheumatology Referral

What else may you add for a suspected infectious etiology?

- ❑ CBC + diff
- ❑ ESR, CRP
- ❑ ANA
- ❑ ds-DNA
- ❑ LFTs
- ❑ LDH
- ❑ Uric Acid
- ❑ Electrolytes
- ❑ Cr, BUN
- ❑ **Viral Serology**
- ❑ **Blood Culture**
- ❑ Urinalysis
- ❑ **Urine Gonorrhea**
- ❑ XR
- ❑ **ASOT and Throat Swab**
- ❑ US
- ❑ **MRI**
- ❑ **Arthrocentesis**
- ❑ Ophtho Referral
- ❑ Rheumatology Referral

PEARL: Antinuclear Antibodies (ANA)

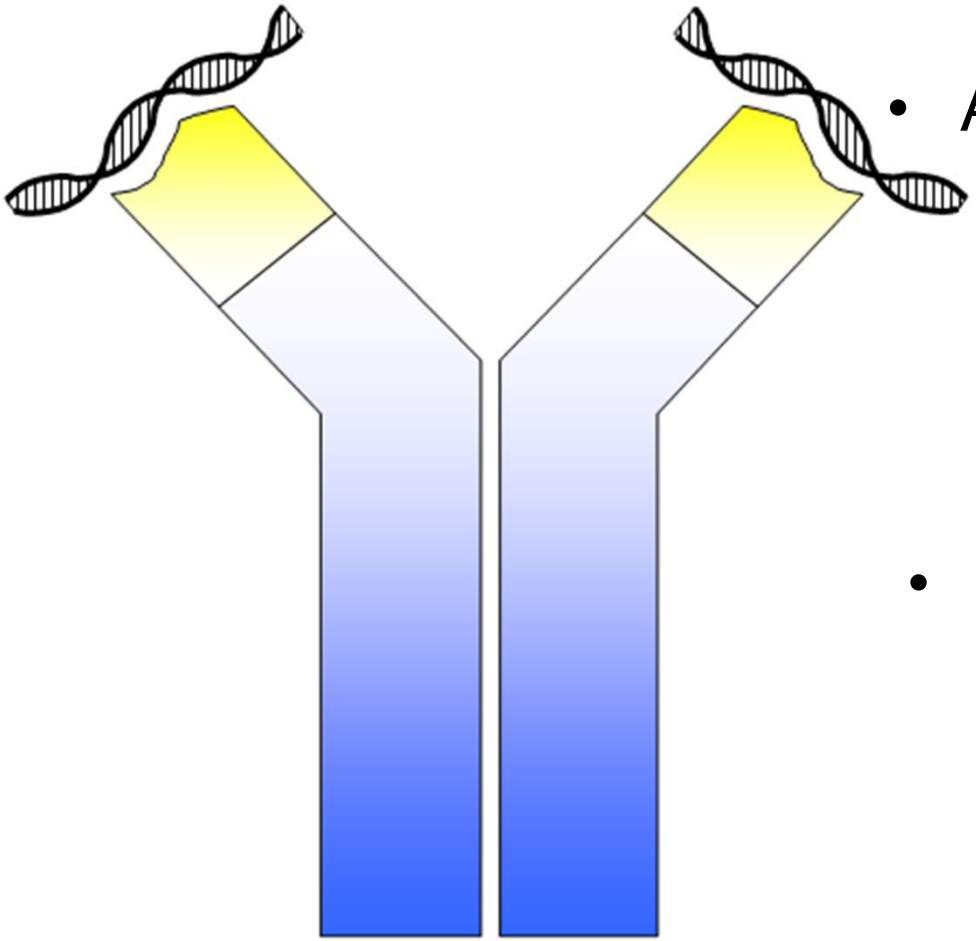

- A proportion of the healthy population will be ANA +
- Order when high probability of systemic autoimmune disease
- + ANA can also be from medication, cancer or infection
- JIA + ANA is associated with increased risk of asymptomatic uveitis

Wikiwand.com

Case: What Did We Find

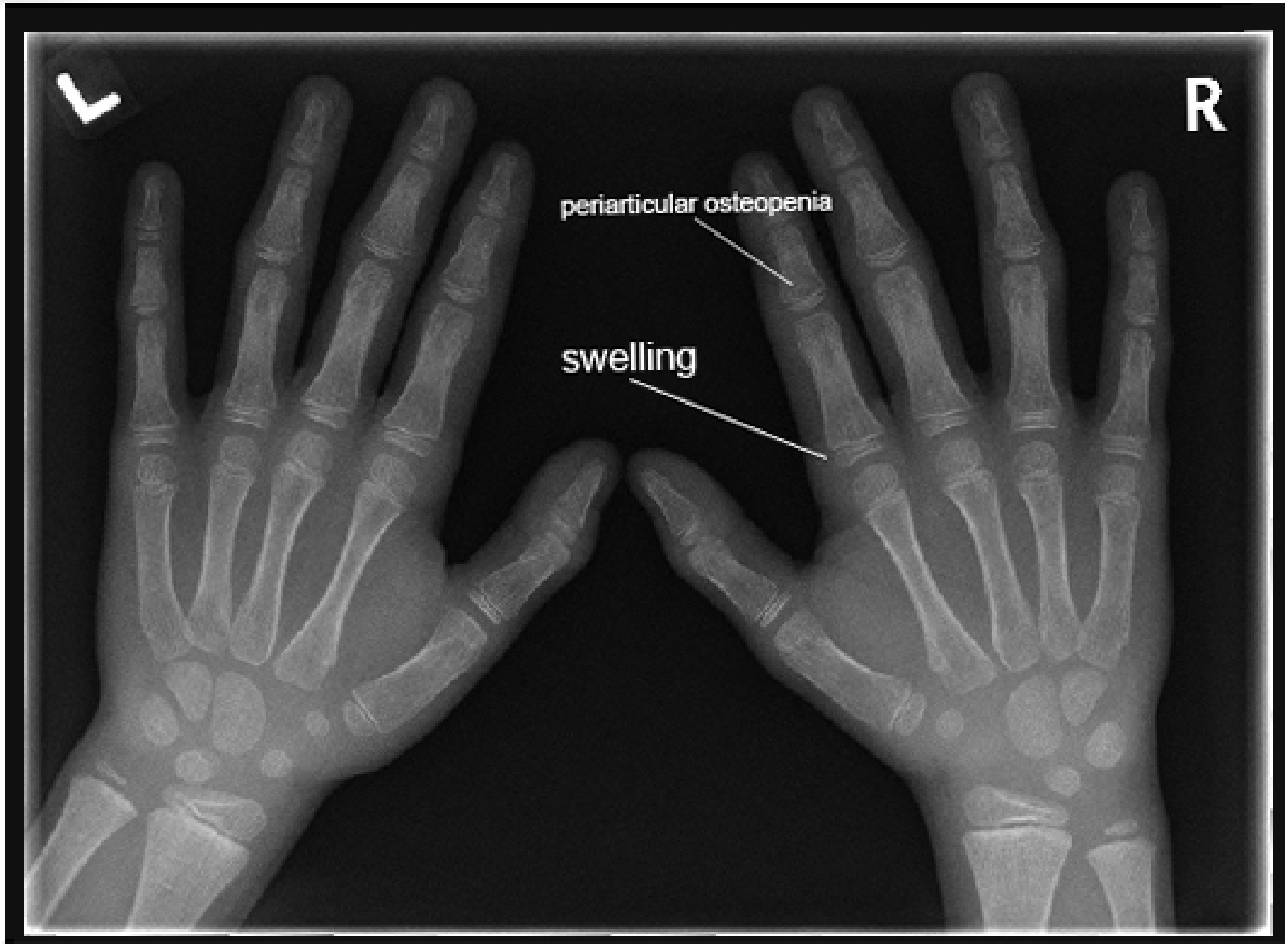

i-LEARN module

What Are Other X-Ray Findings?

Lucent metaphyseal band seen in leukemia

med-ed.virgina.edu/courses/rad/peds

What Are Your Next Steps?

- Clarify the most likely diagnosis
- Treatment
- Referrals
- Follow up and monitoring

Case: Etiology and Treatment

- Clarify the most likely diagnosis
  - JIA is diagnosis of exclusion
- NSAID
  - naproxen 15mg/kg/day divided BID with food
- Consider PPI

Case: Referrals

- Rheumatology referral
- Eye evaluation
  - Optometrists or ophthalmologists

Case: Follow up and Monitoring

- Reassess symptoms and evaluate response/progression
- Assess adherence
- Monitor for medication side effects

Take Home Points

- Differentiate between Inflammatory and mechanical pain
- Always consider infectious, malignant and traumatic causes
- A red, hot, immobile joint is NOT JIA
- pGALS is an effective MSK screening tool

References

- Lee, Jennifer. CHEO i-LEARN module
- Hospital for Sick Children. Residents Guide to Pediatric Rheumatology
- Uptodate

Thank You and Extra Resources

- MSK examinations:
  - https://fhs.mcmaster.ca/medicine/rheumatology/examine-hip.htm
- pGALS website
  - http://www.arthritisresearchuk.org/health-professionals-and-students/video-resources/pgals.asp
- Check out the pGALS app
  - Available on IPhones and Androids!