Evaluation of Heart Murmurs in Children

Jessica White, PGY3

Telehealth Rounds

February 10th, 2017

Outline

- Signs and Symptoms of Cardiac Disease
- Innocent vs Benign Murmurs
- Cardiac Anomalies and Findings
- Diagnostic Work-Up?
- Reasons to Refer

Congenital Heart Disease

- Presentation
  - Cyanosis
  - Tachypnea
  - Shock
- Lesions
  - Mixing
  - L-R shunts
  - Obstructive

Murmurs

- Result from normal patterns of blood flow through the heart and vessels
- Most children have a murmur at some point in their life (60-80%)
  - 1% of children have CHD
  - CHD may or may not have a murmur

History

- Symptoms
  - Infants
    - Feeding difficulty (fatigue), dyspnea, diaphoresis, cyanosis, edema, FTT
  - Children
    - SOBOE, fatigue, exercise intolerance, chest pain*, palpitations, syncope*, cyanosis, squatting, edema, FTT
- Prenatal Hx
  - Alcohol, SSRIs, lithium, valproate, infection, DM
- Neonatal Hx
  - Gestation, hypoxia, MAS
- PMHx
  - Syndrome/ congenital anomalies, frequent respiratory infections, Kawasaki, rheumatic fever
  - Growth and developmental delay
- FamHx
  - CHD (VSD, MVP), HCM, SCD, SCID

CHEO

uOttawa

Table 2. Symptoms Suggesting Cardiac Disease

Symptom or sign	*Significance*
Cardiovascular	
Chest pain	May be related to aortic stenosis or hypertrophic cardiomyopathy
Cyanosis	Structural heart lesion with restricted pulmonary blood flow
Dizziness	Multiple potential causes, including hypoxia and CHF
Near-syncope or syncope	May be related to aortic stenosis or hypertrophic cardiomyopathy
Palpitations	May be related to arrhythmias secondary to structural heart lesions
Constitutional	
Developmental delay	Congenital heart lesions are more common in children with certain genetic disorders and syndromes
Diaphoresis	May indicate CHF or poor cardiac fitness
Easily fatigued	May indicate CHF, hypoxia, or poor cardiac fitness
Poor exercise tolerance or capacity for play	May indicate CHF, hypoxia, or poor cardiac fitness
Poor growth or failure to thrive	May indicate CHF, poor cardiac fitness, or a genetic disorder or syndrome; poor weight gain most commonly reflects decreased cardiac output or left-to-right shunts with pulmonary hypertension
Respiratory	
Asthma-like symptoms	Cardiac asthma resulting from pulmonary congestion
Chronic cough	Atelectasis or difficulty clearing secretions because of pulmonary vascular congestion
Dyspnea on exertion	May indicate CHF, hypoxia, or poor cardiac fitness

CHF = congestive heart failure.

Information from references 4, 7, and 10.

Physical

- Vitals and Growth
  - Arrhythmia or tachycardia, tachypnea
  - Differential in limb BPs
  - Hypoxia (pre or post ductal)
  - Abnormal growth
- Observation
  - Dysmorphisms/ congenital anomalies
  - Central cyanosis
  - Edema (often periorbital)
  - Orthopnea
  - Neck vein distention
  - Precordial activity
  - Defective sternum
  - Digital clubbing
  - Asymmetry to chest wall

Physical

- Pulses
  - Rate, rhythm, volume and character (brachial, femoral)
    - Bounding
    - Decreased
    - Synchronous
  - Capillary refill time
- Lungs
  - Crackles or wheeze
- Abdomen
  - Hepatomegaly
  - Situs invertus
  - Ascites
- Palpation (Precoridum)
  - Heaves
  - Hyperdynamic
  - Thrills
- Auscultation…
  - Mitral
  - Tricuspid
  - Pulmonary
  - Aortic

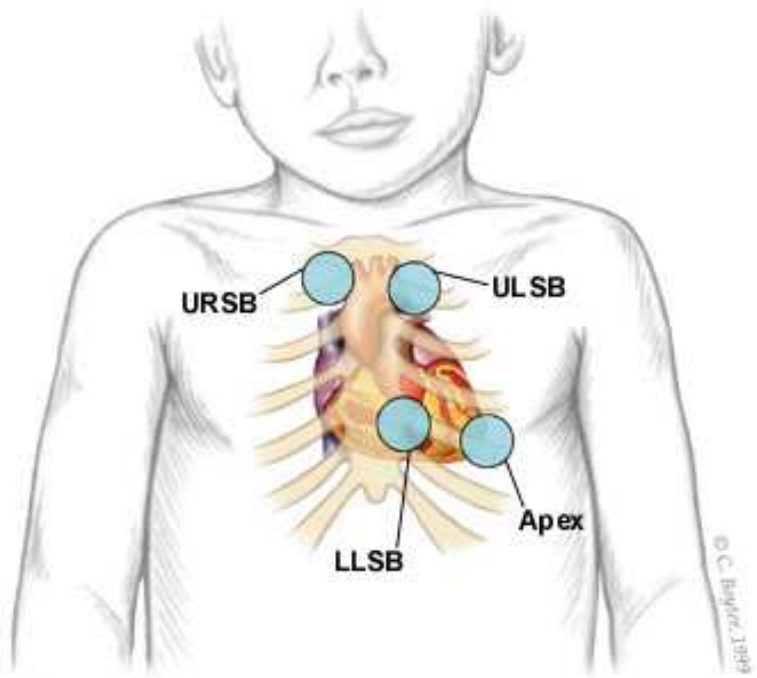

Cardiac Cycle

- http://www.blaufuss.org

Heart Sounds: S1

- AV valve closure
- Split: MV closes then TV closes
  - Wide splitting= bicuspid aortic valve

Heart Sounds: S2

- Closure of semilunar valves
- AV then PV
- Important Sound!
  - Normally split
  - Moves! (ie. narrow in expiration, wide in inspiration)
  - Widened split= RBBB, PS, ASD (fixed)
- Single= pulmHTN and TGA

Heart Sounds: S3

- Rapid filling of ventricles (flow)
  - Normal in children
  - Often disappears when upright

Heart Sounds: S4

- Stiff ventricles
  - Pathologic

Extra Sounds

- Ejection Clicks
  - When PV or AV opens (systole)
    - PV Click (PS): Heard loudest over PV in expiration
    - AV Click (AS): heard loudest over apex
  - Sharp sound after S1 (may sound like split S1)
    - Accompanied by ejection murmurs
- Opening Snaps
  - When TV or MV opens (diastole)
    - Indicates stenotic valve
    - Heard loudest over corresponding valve
- Midsystolic Click/ Whoop
  - Mitral valve prolapse
    - More common in tall females
  - Mid to late systole
  - Best heard standing and leaning forward
  - Varies intensity (moment to moment)

Extra Sounds

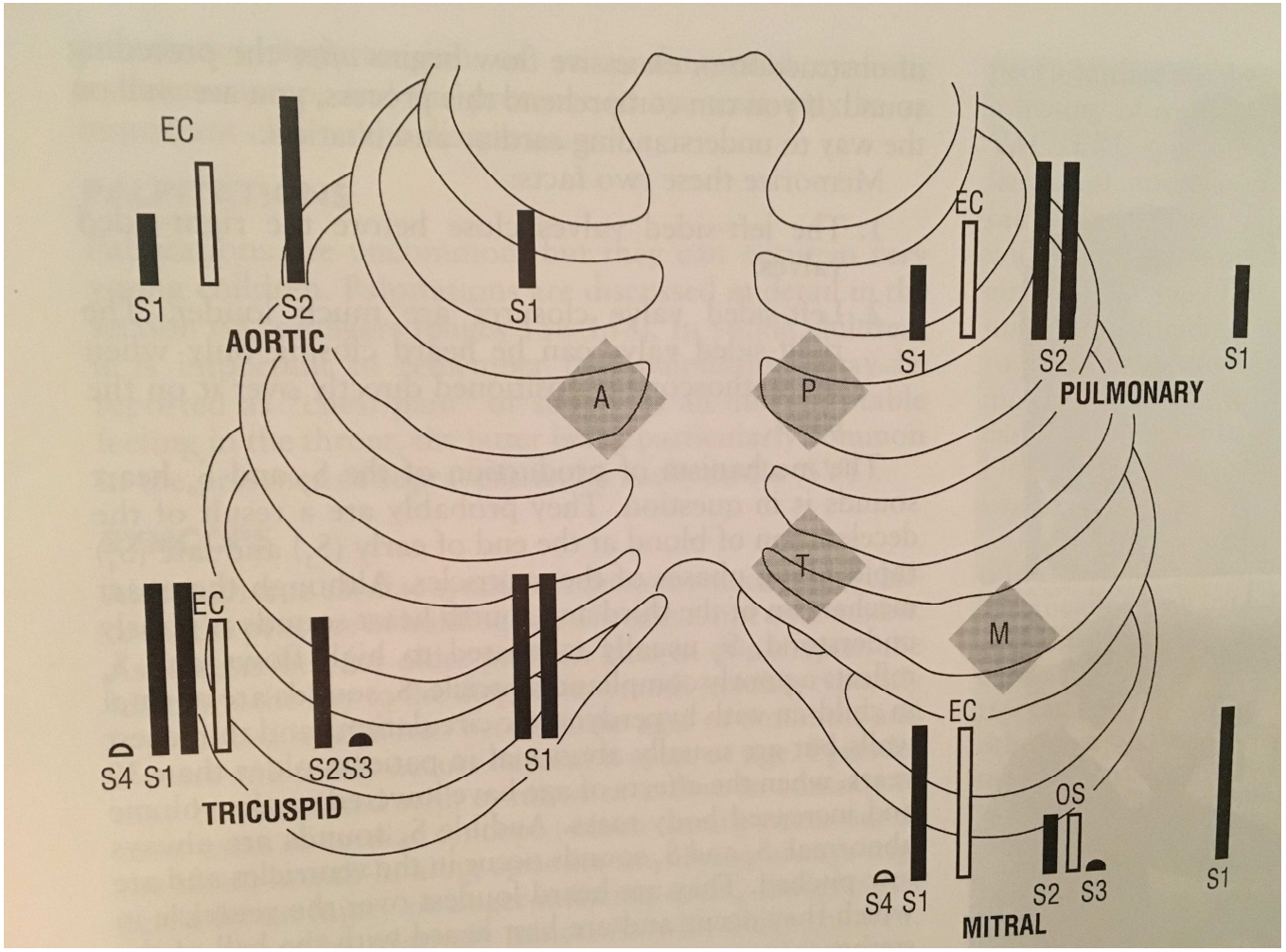

Murmurs: Characteristics

- Timing
- Intensity
- Location
- Duration
- Configuration
- Quality
- Pitch

Murmurs: Grades

- Grade 1: Barely audible
- Grade 2: Audible and constant
- Grade 3: Loud with no thrill
- Grade 4: Loud with thrill
- Grade 5: Stethoscope just touching chest
- Grade 6: Stethoscope off chest

Systolic

- Regurgitation
  - Pansystolic, begin WITH S1
  - Medium pitched (blowing, harsh)
  - Caused by pressure gradient
  - Ex. VSD, MR, TR, MVP
- Ejection
  - Midsystolic, begin AFTER S1
  - Obstruction
    - Low-pitched, coarse, loud
    - Ex. AS, PS, Coarctation
  - Vibration
    - Musical/ string ”twang”
  - Flow
    - Medium pitch and intensity
    - Other signs of high stroke volume
    - Diminishes with standing
    - DDx ASD (fixed split S2)

Diastolic

- Regurgitation
  - Begin WITH S2
  - AR or PR
- Ejection
  - Begin AFTER S2
  - Obstructive
    - MS or TS (uncommon)
  - Vibratory
  - Flow
    - ASD, VSD, MR, TR
    - Increased flow across AV valves

Continuous

- PDA
  - Max intensity LUSB and midclavicular line
  - Peaks in systole with decrescendo diastolic component
  - Bounding pulse, LV heave
- Venous Hum (innocent)

Innocent Murmurs

- Seven S's:
  - Sensitive
  - Short
  - Single
  - Small
  - Soft
  - Sweet
  - Systolic

Innocent Murmurs

- **Still Murmur**
  - Most common (2-6y) due to turbulence in LVOT
  - Musical/vibratory, Gr 1-3 early systolic murmur, low to medium pitch
  - LLSB toward apex
  - Loudest supine, on expiration, decreases with standing
  - Can sound like VSD or HCM
- **Peripheral Pulmonary Stenosis**
  - Blowing/long, Gr 1-2 early to mid-systolic murmur, high-pitched
  - Base of heart, axillae, back
  - Normally split S2, louder as heart rate slows
  - Acute angle of branch PAs in newborn which remodel over time (by 3-6 months)
  - Can sound like PS, normal breath sounds or coarctation (Check femorals!)
- **Pulmonary Flow Murmur**
  - Rough, dissonant, Gr 2-3 early-to-mid ejection systolic murmur
  - ULSB
  - Loudest when supine, decreases when upright and holding breath
  - Can sound like ASD (normally split S2) or PS (normal S2, no click, no diastolic murmur, not hyperdynamic)

Innocent Murmurs

- **Aortic Flow Murmur**
  - Rough, dissonant, Gr 2-3 early-to-mid ejection systolic murmur
  - RUSB, may radiate to carotid
  - Older children into adulthood
- **Supraclavicular Bruit**
  - Brief, low pitch crescendo-decrescendo in early systole
  - Above and below clavicles, radiates to neck, +/- thrill
  - Diminishes when hyperextending shoulders
  - Turbulence in carotid (R>L) with systolic ejection stream into the vessel
  - Sounds like AS but no ejection click, normal S2 and different maximum location
- **Venous Hum**
  - Whining, roaring, whirring Gr 1-6, continuous, systolic/diastolic murmur (3-8y)
  - Supra/infraclavicular (R>L)
  - Sitting or standing (disappears when supine or applied pressure to jugular vein)
  - Caused by blood cascading down jugular vein, louder in diastole as atrium empties
  - DDx PDA
- **Mammary Artery Souffle**
  - High-pitched systolic murmur that can extend into diastole
  - Anterior chest over breast
  - Rare in adolescence
  - Can sound like PDA or AVM

Innocent Murmurs

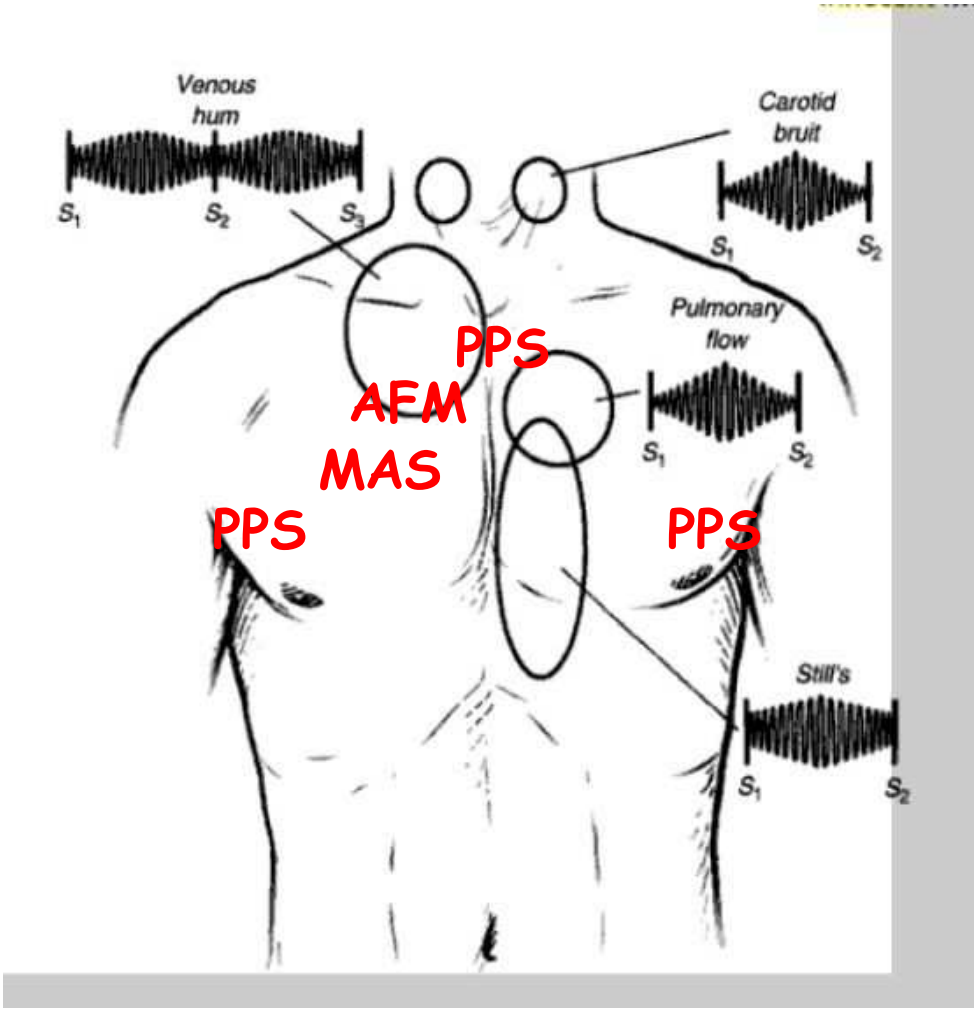

Pathologic Heart Murmurs

- Features associated with CHD
  - Holosystolic
  - Diastolic
  - Grade 3+
  - Harsh quality
  - Systolic Click
  - Abnormal S2
  - Increased precordial activity
  - Decreased femoral pulses
  - Increased with standing/ lifting leg or decreased with squatting

Pathologic Heart Murmurs

- Ejection Murmurs
  - Age
  - ?Hyperdynamic precordium
  - S2
    - ?wide split S2
    - ?Normal split S2 movement
  - Added Sounds
    - ?ejection click
    - ?Diastolic murmur
  - ?Normal peripheral pulses

Pathologic Heart Murmurs

Type of structural heart lesion	*Prevalence among children with congenital heart disease (%)*	*Symptoms and clinical course*	*Characteristics*
Ventricular septal defect	20 to 25	Small defects: usually asymptomatic Medium or large defects: CHF, symptoms of bronchial obstruction, frequent respiratory infections	Small defects: loud holosystolic murmur at LLSB (may not last throughout systole if defect is very small) Medium and large defects: increased right-to-left ventricular impulses; thrill at LLSB; split or loud single S_2; holosystolic murmur at LLSB without radiation; grade 2 to 5; may also hear a grade 1 or 2 mid-diastolic rumble
Atrial septal defect	8 to 13	Usually asymptomatic and incidentally found on physical examination or echocardiography; large defects can be present in infants with CHF	Grade 2 or 3 systolic ejection murmur best heard at ULSB; wide split fixed S_2; absent thrill; may have a grade 1 or 2 diastolic flow rumble at LLSB
Patent ductus arteriosus	6 to 11	May be asymptomatic; can cause easy fatigue, CHF, and respiratory symptoms	Continuous murmur (grade 1 to 5) in ULSB (crescendo in systole and decrescendo into diastole); normal S_1; S_2 may be "buried" in the murmur; thrill or hyperdynamic left ventricular impulse may be present
Tetralogy of Fallot	10	Onset depends on severity of pulmonary stenosis; cyanosis may appear in infancy (2 to 6 months of age) or in childhood; other symptoms include hypercyanotic spells or decreased exercise tolerance	Central cyanosis; clubbing of nail beds; grade 3 or 4 long systolic ejection murmur heard at ULSB; may have holosystolic murmur at LLSB; systolic thrill at ULSB; normal to slightly increased S_1; single S_2
Pulmonary stenosis	7.5 to 9	Usually asymptomatic but may have symptoms secondary to pulmonary congestion	Systolic ejection murmur (grade 2 to 5); heard best at ULSB radiating to infraclavicular regions, axillae, and back; normal or loud S_1; variable S_2; systolic ejection click may be heard at left sternal border and may vary with respiration

Pathologic Heart Murmurs

Coarctation of the aorta	5.1 to 8.1	Newborns and infants may present with CHF; older children are usually asymptomatic or may have leg pain or weakness	Systolic ejection murmur best heard over interscapular region; normal S_1 and S_2; decreased or delayed femoral pulse; may have increased left ventricular impulse
Aortic stenosis	5 to 6	Usually asymptomatic; symptoms may include dyspnea, easy fatigue, chest pain, or syncope; newborns and infants may present with CHF	Systolic ejection murmur (grade 2 to 5) best heard at upper right sternal border with radiation to carotid arteries; left ventricular heave; thrill at ULSB or suprasternal notch
Transposition of the great arteries	5	Variable presentation depending on type; may include cyanosis or CHF in first week of life	Cyanosis; clubbing of nail beds; single S_2; murmur may be absent or grade 1 or 2 nonspecific systolic ejection murmur; may have a grade 3 or 4 holosystolic murmur at LLSB and mid-diastolic murmur at apex
Total anomalous pulmonary venous connection	2 to 3	Onset of CHF at 4 to 6 weeks of age	Grade 2 or 3 systolic ejection murmur at ULSB; grade 1 or 2 mid-diastolic flow rumble at LLSB; wide split fixed S_2
Tricuspid atresia	1.4	Early-onset cyanosis or CHF within the first month of life	Cyanosis; clubbing of nail beds; normal pulses; single S_2; holosystolic murmur at LLSB or midsternal border; murmur may be absent; mid-diastolic flow murmur at apex may be present
Hypoplastic left heart syndrome	Rare	May be asymptomatic at birth, with cyanosis and CHF developing with duct closure	Hyperdynamic precordium; single S_2; nonspecific grade 1 or 2 systolic ejection murmur along left sternal border
Truncus arteriosus	Rare	Onset of CHF in first few weeks of life; minimal cyanosis	Increased cardiac impulses; holosystolic murmur (ventricular septal defect); mid-diastolic rumble

Work-Up

- CXR and ECG rarely assist in diagnosis
  - Does not improve sensitivity or specificity[1]
  - More likely to mislead than assist[2]
  - Abnormal finding on history, physical exam or test (ECG, CXR or SpO2) with innocent sounding murmur[3]
    - <6 weeks old: Likelihood ratio of 1.0
    - >6 weeks old: Likelihood ratio of 1.6 and 0.026
    - Therefore, helpful in older only
- Phonocardiography (digital heart sound recordings)
  - High sensitivity and specificity, good intraobserver agreement of innocent vs potential pathologic requiring echocardiography[4]

When NOT to Refer

- Innocent Murmur
  1. Absence of abnormal physical examination findings
  2. Negative ROS
  3. No features that increase risk for structural heart disease
  4. Characteristic features of specific innocent heart murmur
  5. AND >1 year
- If innocent murmur cannot be definitely diagnosed, referral warranted

When to Refer

- Red Flags
  - Infant with FTT
  - Central Cyanosis
  - Decreased femoral pulses
  - Syncope or SOB with exertion
  - Infantile murmurs persisting >1 year
  - Murmurs heard best in the back
  - Abnormal S1 or S2
  - Harsh, loud, long murmurs
  - Diastolic murmurs

References

1. Macie, AS et al. Can cardiologists distinguish innocent from pathologic murmurs in neonates? *J Pediatr.* 2009;154(1):50-54.
2. Rajakumar K et al. Comparative study of clinical evaluation of heart murmurs by general pediatricians and pediatric cardiologists. *Clin Pediatr (Phila).* 1999;38(9):511-518.
3. Danford, DA et al. Echocardiographic yield in children when innocent murmur seems likely but doubts linger. *Pediatr Cardiol.* 2002;23(4):410-414.
4. Germanakis, I et al. Digital phonocardiography as a screening tool for heart disease in childhood. *Acta Paediatr.* 2008;47(9):919-925.
5. Goldbloom, RB. Pediatric Clinical Skills, 4th Ed, 2011.
6. Menashe, V. Heart Murmurs. *Pedsinreview*, 2007; 28(4).
7. Frank, JE and Jacobe, KM. Evaluation and Management of Heart Murmurs in Children. *Am Fam Physician*, 2011; 84(7):793-800.
8. Pelech, A. Evaluation of the Pediatric Patient with a Cardiac Murmur: *Pediatric Cardiology*, 1999; 46(2):167-188.