CHEO
child & youth

Pediatric Telehealth Rounds

Today's topic:

Innocent heart murmurs

Speaker:

Ashraf Kharrat
PGY-3 Pediatrics

Date

If you are connected by videoconference:

Please mute your system while the speaker is presenting.

Please feel free to ask questions!

By registering for today's event…

You will have had an opportunity to apply for **professional credits** or a **certificate of attendance**

You will receive an email with a link to today's **online evaluation**

You may also want to…

Visit our website to download **slides** and view **archived events**

Sign-up to our **distribution list** to receive our event notifications

Questions?
pedtelehealthrounds@cheo.on.ca

Declaration of conflict

Speaker has nothing to disclose with regard to commercial support.

Speaker does not plan to discuss unlabeled/ investigational uses of commercial product.

Objectives

- Review pediatric cardiac exam
- Outline how to describe murmurs
- Discuss innocent heart murmurs
- Identify red flags

Cardiac physiology

- first heart sound S1
  - closure of atrioventricular (TV MV) in early isovolumic ventricular contraction
  - MV closes just slightly before TV due to pressure gradient but normally a single heart sound

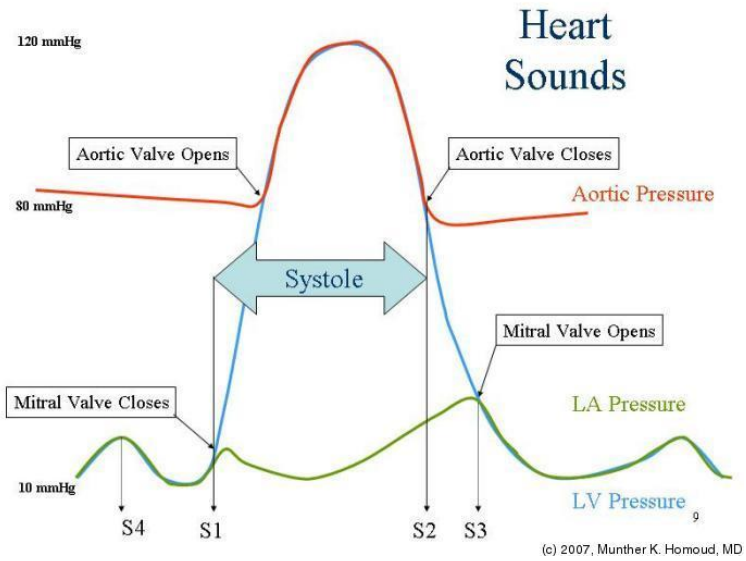

Cardiac physiology

- second heart sound S2
  - closure of semilunar (AV PV)
  - louder and earlier AV closure
  - splitting more prominent in inspiration; increased right heart filling means longer emptying so bigger delay in closing

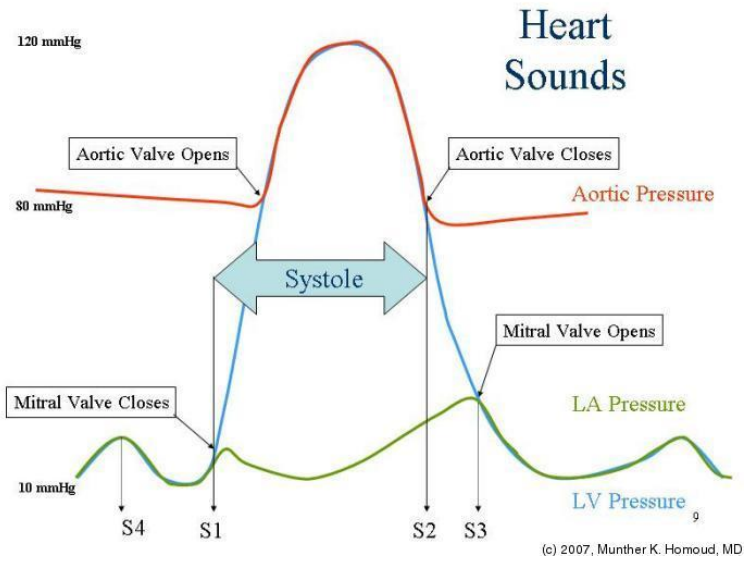

Taking a cardiac history

- symptoms
  - failure to thrive, feeding difficulties, shortness of breath, chest pain, sweating or tachypnea with feeds, syncope, excessive fatigue
- family history
  - sudden death, SIDS, structural cardiac abnormality in first-degree relative, hypertrophic cardiomyopathy
- pregnancy history
  - GDM, maternal illnesses, infections, drug use

Cardiac exam

- vital signs
  - respiratory rate: tachypnea occurs secondary to increased pulmonary flow
  - blood pressure: UL usually; some suggest every child should have upper and lower limb BPs documented once in their life
- nutrition status
- plotted height and weight
- cyanosis, pallor, plethora
  - in context of murmur, cyanosis suggests structural lesion with restriction of pulmonary blood flow
- dysmorphisms

Cardiac exam

- pulses
  - rate, rhythm, volume, character
  - CRT
- JVP as measure of right atrial pressure
  - older kids
- liver character and size as indicators of systemic congeston
  - should be sharp and angulated, not rounded and full
  - newborns: 2.5-3cm BCM midclavicular
  - 1yo: 1-2cm BCM
  - school aged: not always palpable

Cardiac exam

- apical impulse
  - should not be more than one intercostal space
  - normally at midclavicular line

Describing a murmur: location

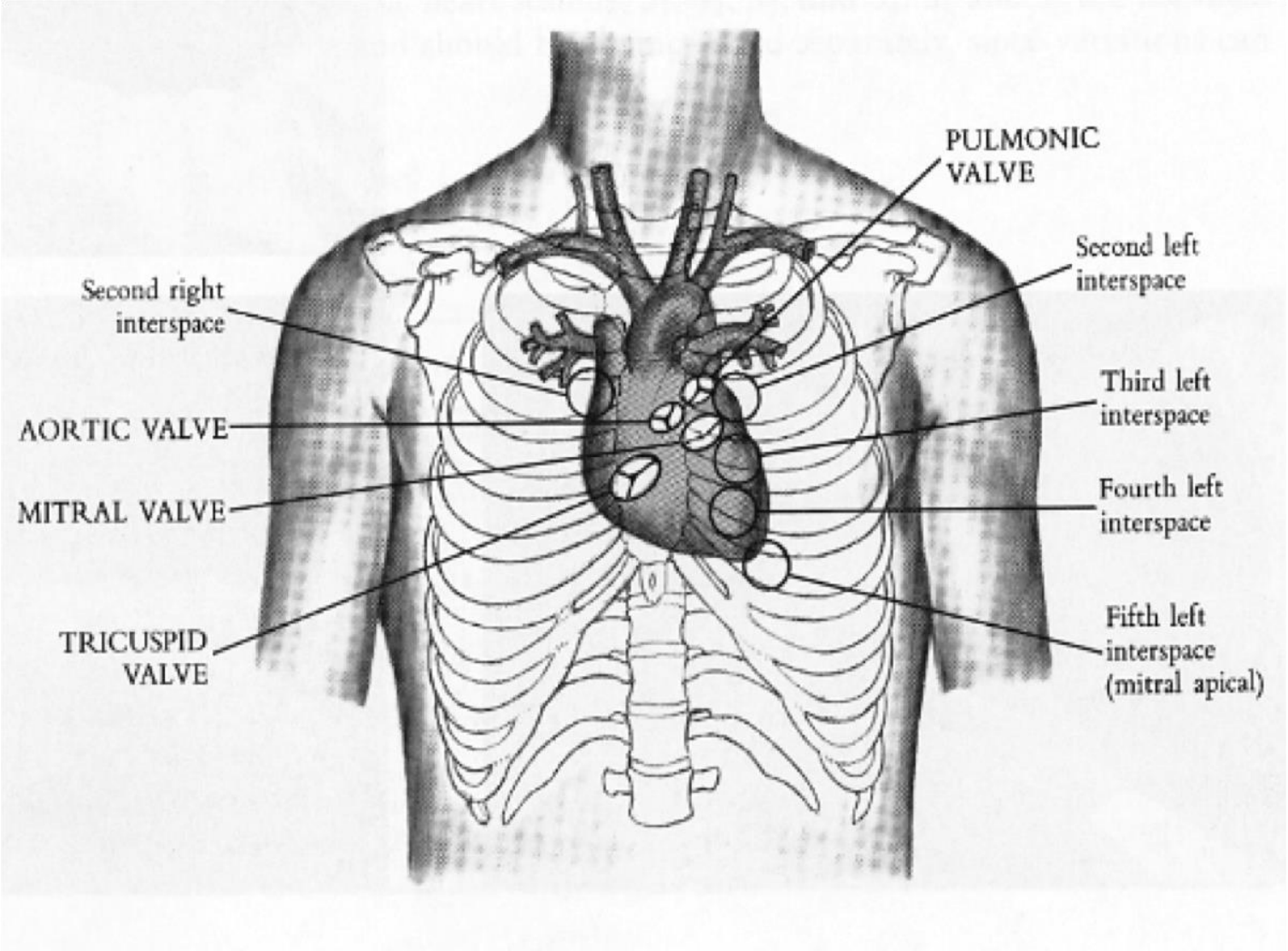

Murmurs

- produced by
  - backward regurgitation through leaky valve or septal defect
  - forward flow through narrowed or deformed valve or arteriovenous connection
  - turbulent blood flow
  - vibration of loose structures within heart (eg: chordae tendinae or valvular tissue)

Murmurs

- six characteristics to consider
  - location (area where sound is loudest)
  - frequency (low or high pitch)
  - intensity (I-VI grading system)
  - quality (blowing, harsh, rumbling)
  - timing (systolic, diastolic, both)
  - radiation

Describing a murmur: grading

- I barely audible
- II soft, but easily audible
- III moderately loud without thrill
- IV loud with a thrill
- V audible with stethoscope barely on chest
- VI audible with stethoscope off chest

Innocent vs pathologic

- Innocent
  - quiet (grade I-II)
  - early systolic
  - poorly transmitted
  - not associated with other findings
- Pathologic
  - loud (grade III+)
  - diastolic
  - abnormal heart sounds (e.g. S3, S4, click)
  - abnormal or absent pulses
  - unequal blood pressures
  - cyanosis
  - symptoms (e.g. syncope, chest pain)

Innocent vs pathologic

- Syndromes, dysmorphisms, other congenital anomalies (e.g. CHARGE syndrome, 22q11 deletion, trisomy 21)

Syndrome	Dominant Cardiac Defect
Alagille (arteriohepatic dysplasia)	Peripheral pulmonary stenosis
Asplenia	Complex cyanotic heart disease, anomalous veins, pulmonary atresia
Carpenter's	Patent ductus arteriosus, ventricular septal defect
CHARGE	Ventricular, atrioventricular, and atrial septal defects
Cri-du-chat (deletion 5p)	Variant forms of congenital abnormalities
de Lange's	Tetralogy of Fallot, ventricular septal defect
DiGeorge	Aortic arch anomalies, tetralogy of Fallot
Down	Atrioventricular septal defects, ventricular septal defect
Ellis-van Creveld	Single atrium
Fanconi's	Patent ductus arteriosus, ventricular septal defect
Fetal alcohol	Ventricular septal defect, atrial septal defect, tetralogy of Fallot
Fragile X	Mitral valve prolapse, aortic root dilation
Goldenhar's	Tetralogy of Fallot
Holt-Oram	Atrial or ventricular septal defect
Hydantoin	Atrial or ventricular septal defect, coarctation
Infant of diabetic mother	Hypertrophic cardiomyopathy, ventricular septal defect
Laurence-Moon-Biedl	Tetralogy of Fallot, ventricular septal defect
Marfan's	Aortic root dissection, mitral valve prolapse
Mulibrey nanism	Pericardial thickening, constrictive pericarditis
Multiple lentigenes (leopard)	Pulmonary stenosis
Noonan's	Pulmonic stenosis, atrial septal defect
Polycystic kidney disease	Mitral valve prolapse
Polysplenia	Complex acyanotic lesions, azygous continuation
Rubella	Patent ductus arteriosus, peripheral pulmonary stenosis
Rubinstein-Tayba	Patent ductus arteriosus
Scimitar	Hypoplasia of the right lung, anomalous pulmonary drainage
Smith-Lemli-Opitz	Ventricular septal defect, patent ductus arteriosus
Thrombocytopenia-absent radius (TAR)	Atrial septal defect, tetralogy of Fallot
Trisomy D	Ventricular septal defect, patent ductus arteriosus
Trisomy E	Ventricular septal defect, patent ductus arteriosus
Turner's	Coarctation of the aorta, bicuspid aortic valve
Valproate effects	Coarctation, hypoplastic left heart
Velocardiofacial	Ventricular septal defect, right aortic arch
Williams	Supravalvular aortic stenosis, peripheral pulmonary stenosis
Wolf	Atrial septal defect, ventricular septal defect

Innocent heart murmurs

- >80% of kids will have one at some point
- no structural abnormalities
- louder in high output states
  - exercise
  - fever
  - illness
- 1% of children have congenital heart disease

Innocent heart murmurs

- Systolic
  - Still's
  - Pulmonary flow murmur
  - Peripheral pulmonary stenosis (PPS)
  - Carotid bruit
- Continuous
  - Venous hum

Table 2–9. ***Common Innocent Heart Murmurs***

Type (Timing)	Description of Murmur	Age Group
Classic vibratory murmur (Still's murmur) (systolic)	Maximal at MLSB or between LLSB and apex Grade 2 to 3/6 Low-frequency vibratory, "twanging string," groaning, squeaking, or musical	3–6 yr Occasionally in infancy
Pulmonary ejection murmur (systolic)	Maximal at ULSB Early to midsystolic Grade 1 to 3/6 in intensity Blowing in quality	8–14 yr
Pulmonary flow murmur of newborn (systolic)	Maximal at ULSB Transmits well to the left and right chest, axilla, and back Grade 1 to 2/6 in intensity	Prematures and full-term newborns Usually disappears by 3–6 mo of age
Venous hum (continuous)	Maximal at right (or left) supraclavicular and infraclavicular areas Grade 1 to 3/6 in intensity Inaudible in the supine position Intensity changes with rotation of the head and compression of the jugular vein	3–6 yr
Carotid bruit (systolic)	Right supraclavicular area and over the carotids Grade 2 to 3/6 in intensity Occasional thrill over a carotid	Any age

LLSB, lower left sternal border; MLSB, mid-left sternal border; ULSB, upper left sternal border.

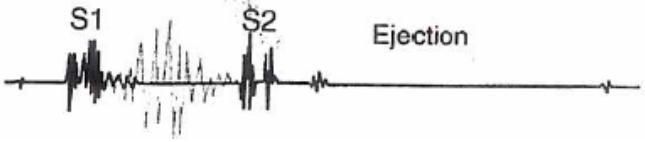

(1) Still's murmur

- Most common innocent murmur, usually found between the ages of 3 and 6
- Thought to be due to turbulence in LV outflow or to vibration of fibrous tissue bands crossing LV lumen

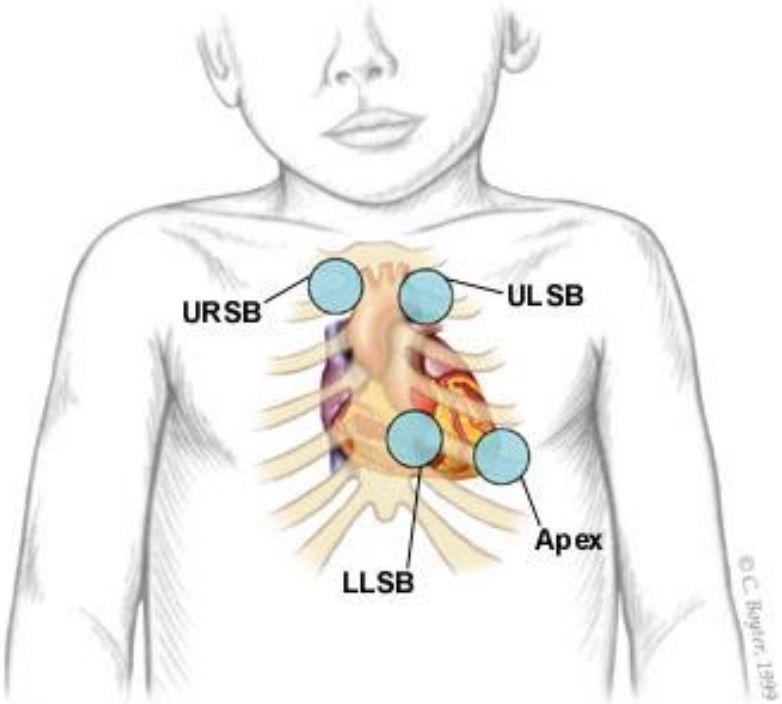

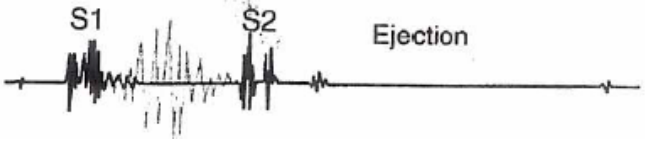

(1) Still's murmur

- Typically grade II-III, midsystolic, LLSB, and classically described as "vibratory"
- Decreases with standing, loudest supine
- Increases with fever, exercise, anemia

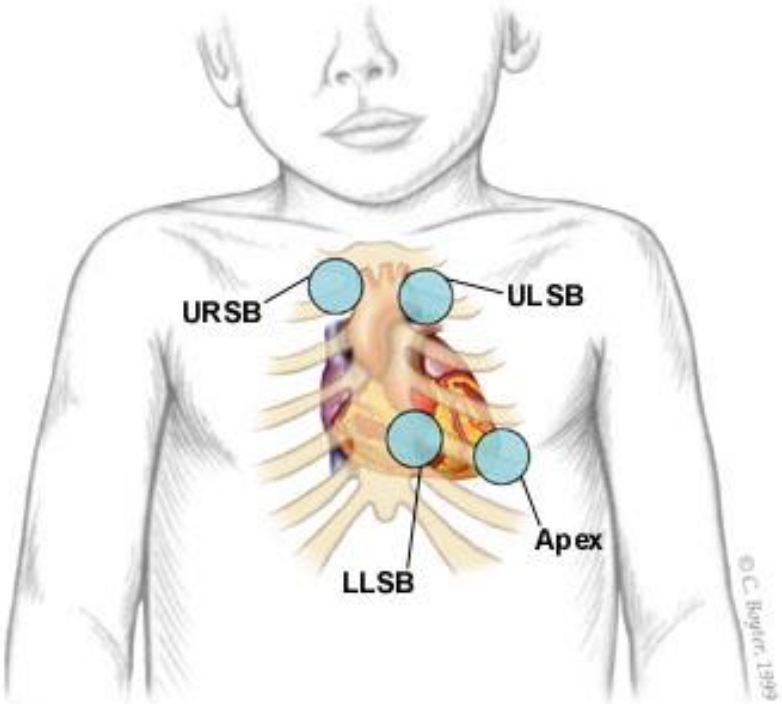

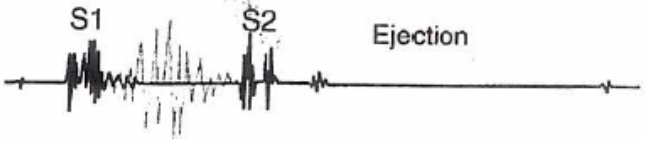

(1) Still's murmur

- Distinguish VSD murmur
  - harsh, blowing
  - holosystolic (may not hear S1/S2)
  - +/- thrill
  - +/- abnormal EKG

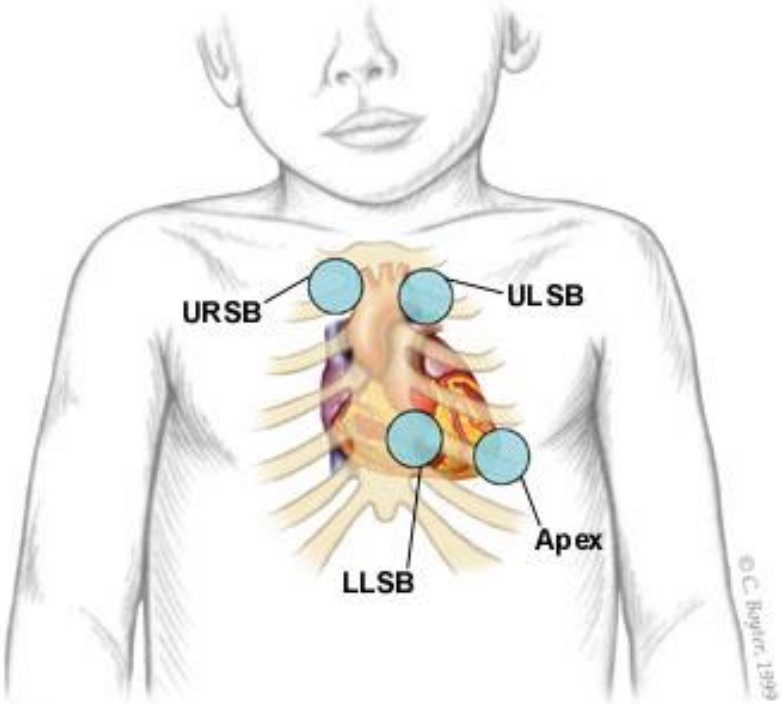

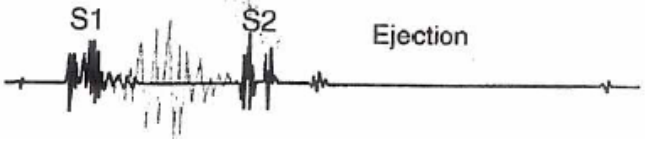

(2) Pulmonary flow murmur

- Accounts for 15% of all innocent murmurs
- Heard in infants and school-aged children
- Due to turbulent flow at the origin of the right and left pulmonary arteries

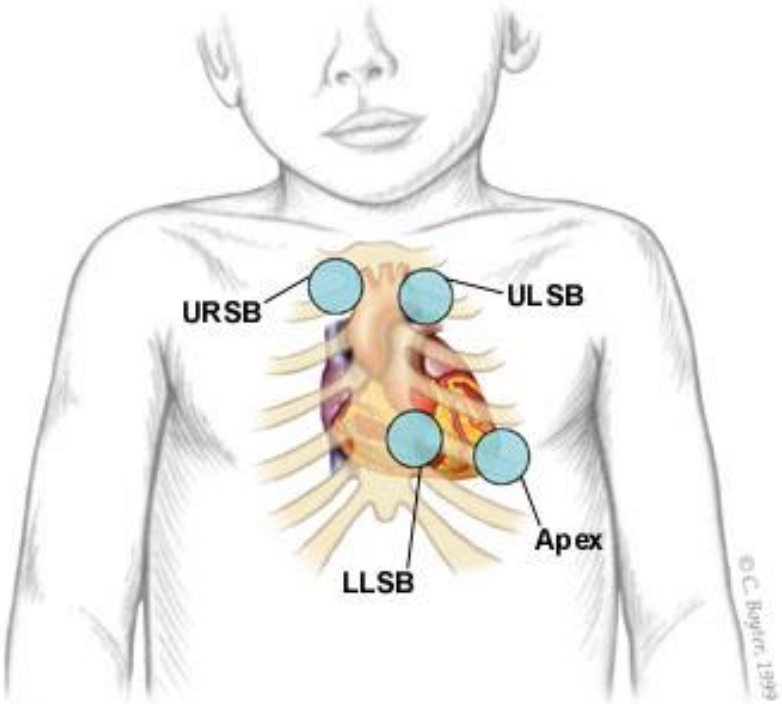

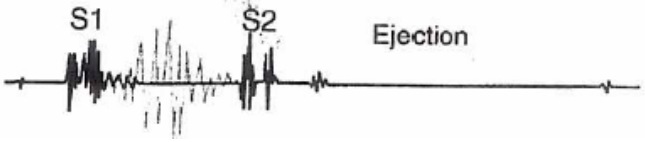

(2) Pulmonary flow murmur

- Grade I-III, crescendo-decrescendo, midsystolic peak, LUSB, radiation to axilla and back, higher pitched than a Still's murmur
- Like Still's, increases with fever, exercise, and anemia

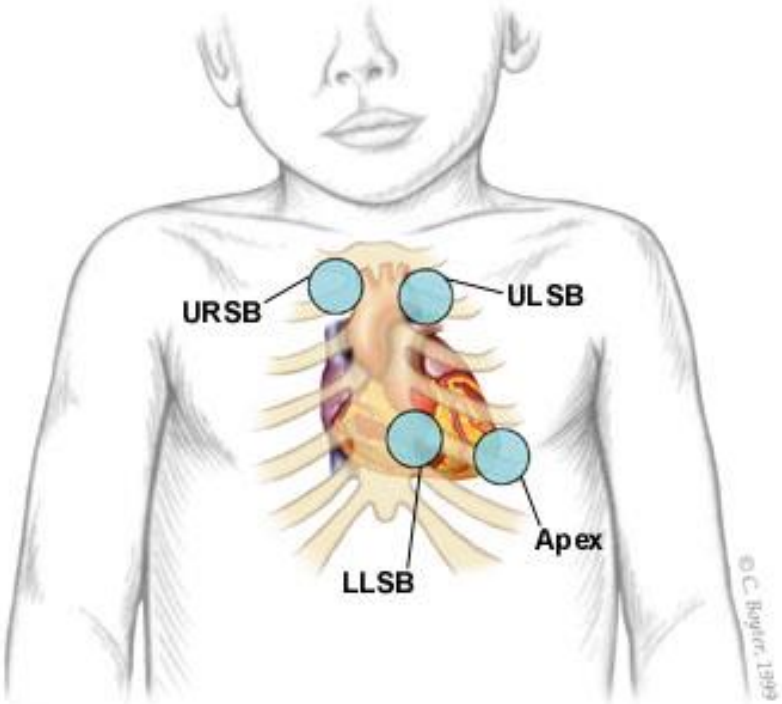

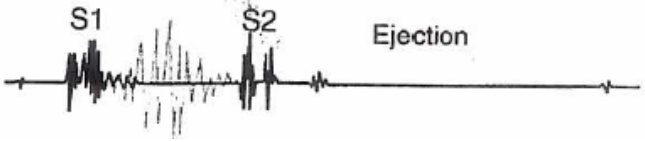

(2) Pulmonary flow murmur

- Distinguish ASD murmur
  - actually due to increased pulmonary outflow tract flow
  - differentiate with hyperdynamic RV impulse, wide splitting S2
- Distinguish PS murmur
  - higher pitch, longer duration, presence of ejection click

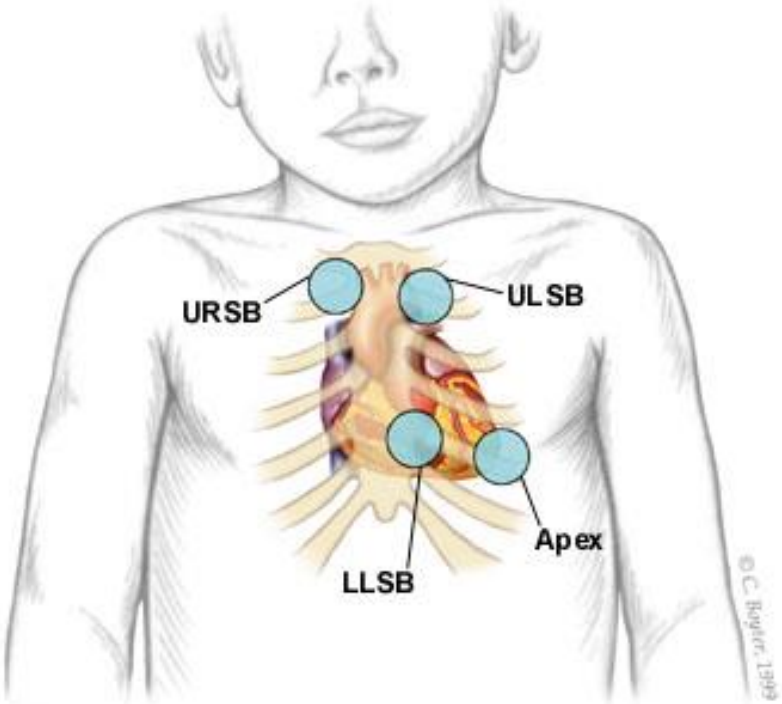

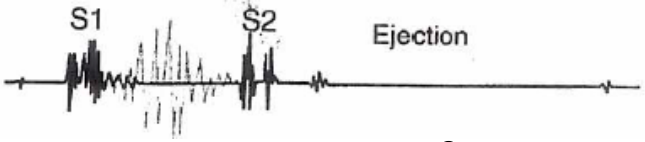

(3) Peripheral pulmonary stenosis

- Due to the physiologic relative stenosis or angulation of the right and left pulmonary arteries
- Grade I-II, low pitched, systolic ejection, LUSB, radiation to axilla and back, no thrill
- Usually disappears by 1 year of age
- Normal EKG

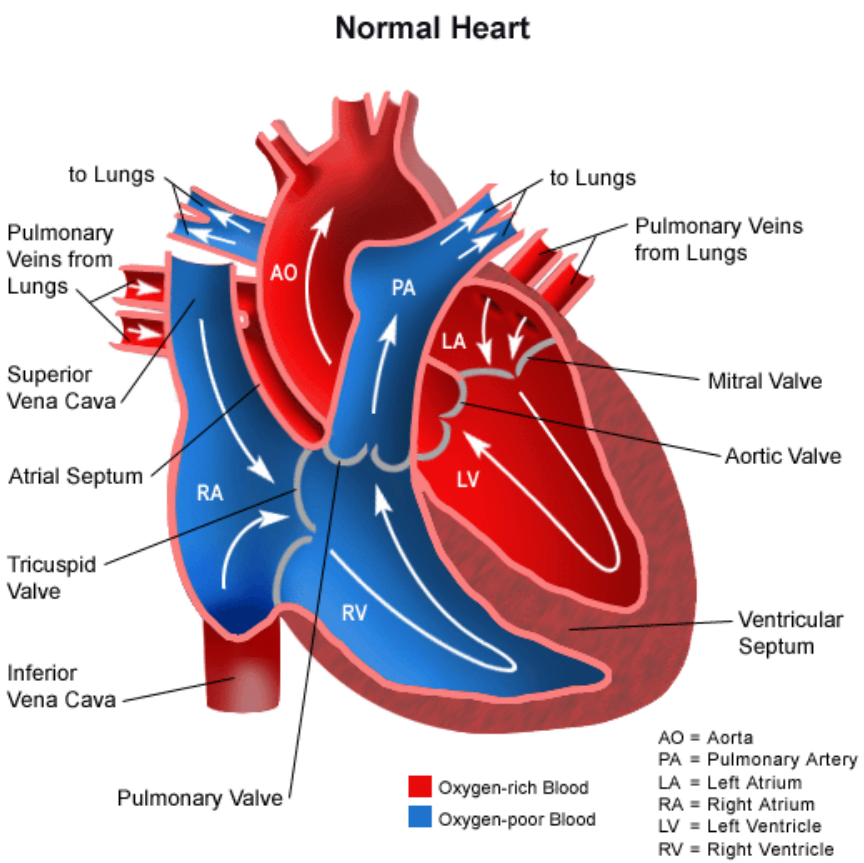

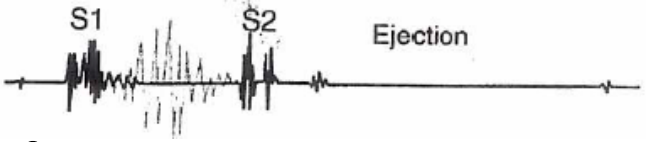

(4) Carotid bruit

- Due to turbulent blood flow from arch into head/neck arteries
- Grade II-III, loudest over carotids
- Any age (toddlers to adolescents)
- Diminished by shoulder maneuver

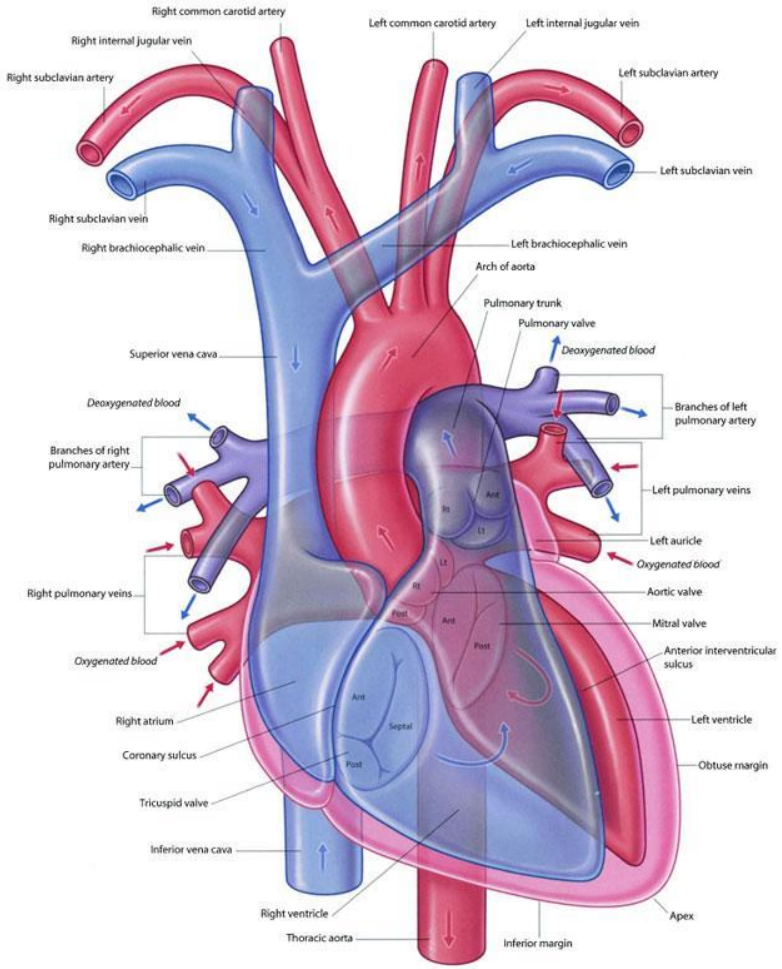

Cardiac chambers and direction of blood flow

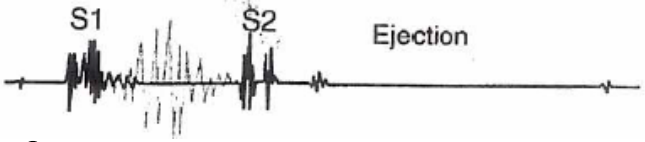

(4) Carotid bruit

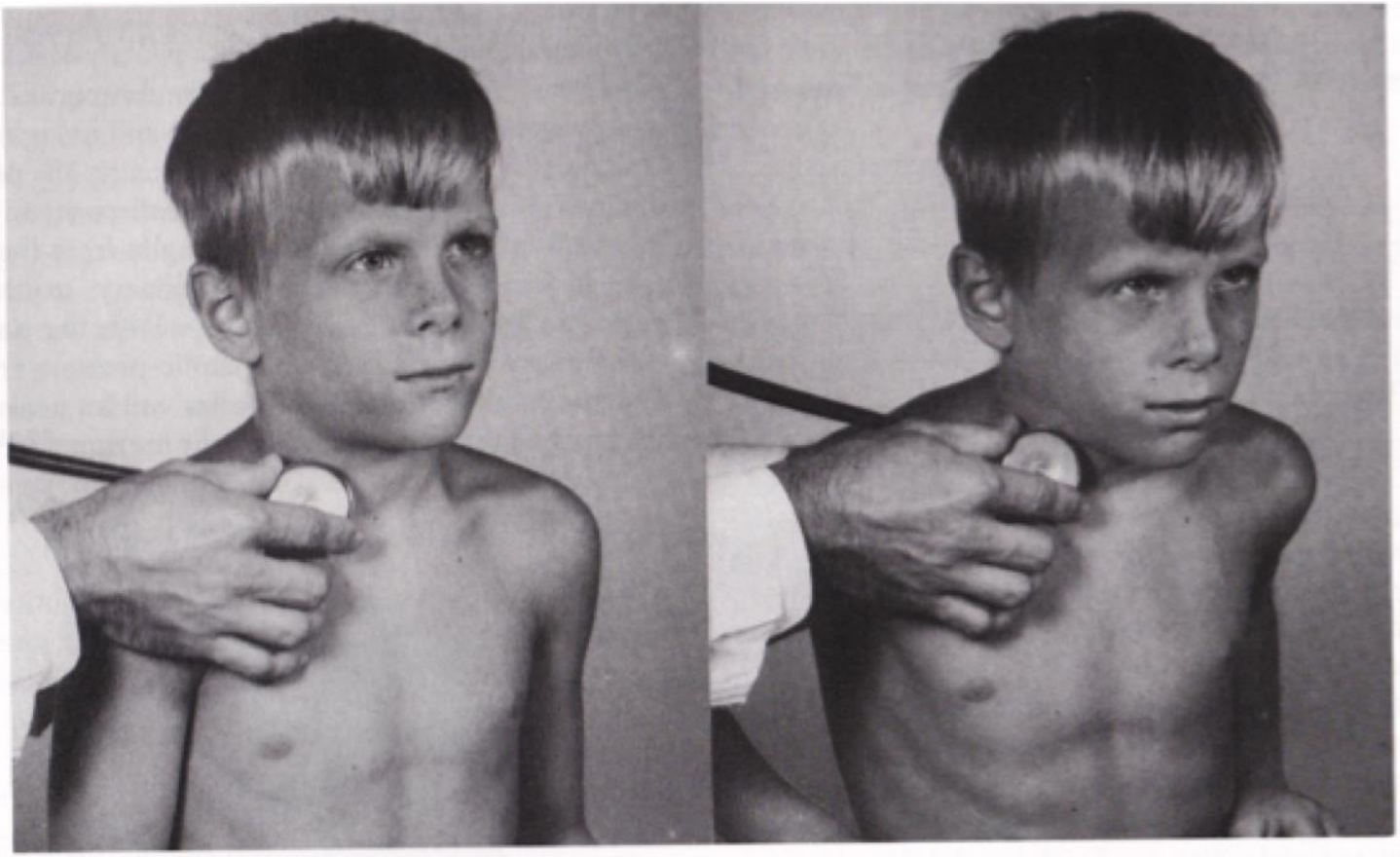

Figure 2–7
A, Shoulder maneuvers for assessing normal supraclavicular systolic murmurs. Auscultation is initially performed while the patient sits with shoulders relaxed and arms in front of the chest. *B*, When the elbows are brought well behind the back, hyperextending the shoulders, the supraclavicular murmur diminishes or disappears.

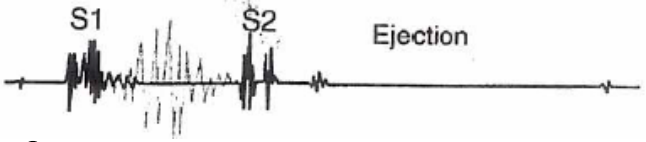

(4) Carotid bruit

- Differentiate AS murmur
  - may transmit to carotid arteries
  - loudest RUSB
  - thrill over RUSB and suprasternal notch
  - ejection click
  - abnormal XR or EKG

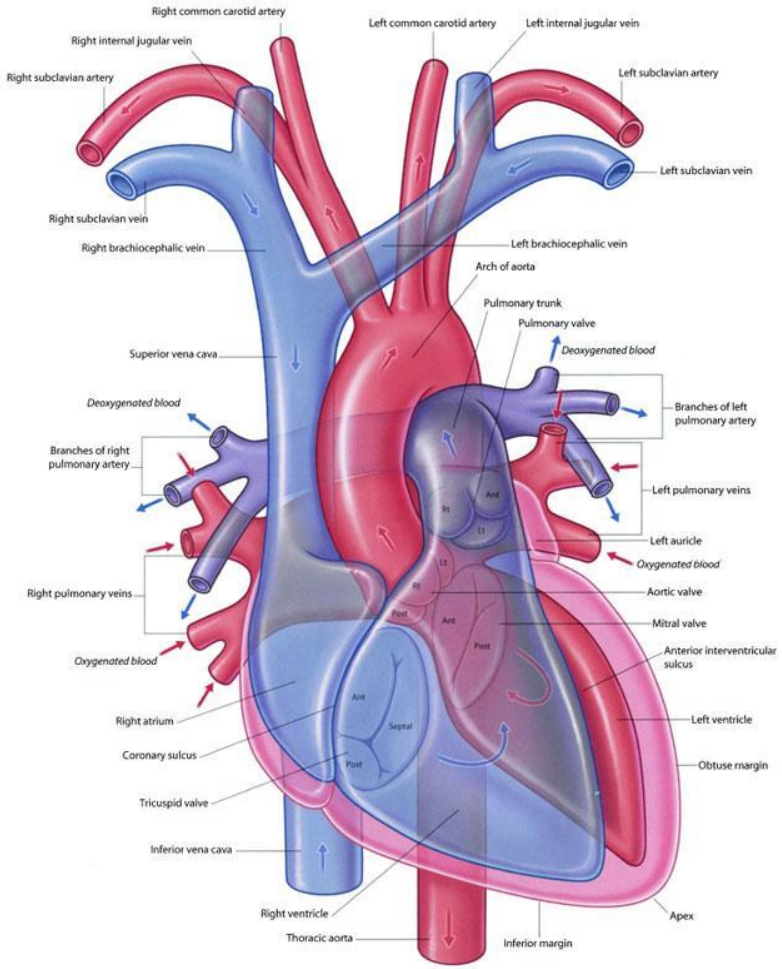

Cardiac chambers and direction of blood flow

(5) Venous hum

- Due to turbulent flow of blood as internal jugular and subclavian veins enter SVC
- Most common continuous murmur, grade I-III, loudest at supra/infraclavicular just lateral to SCM (right > left)
- Compression on IJ and rotation of head will diminish intensity
- Usually age 3-6yo

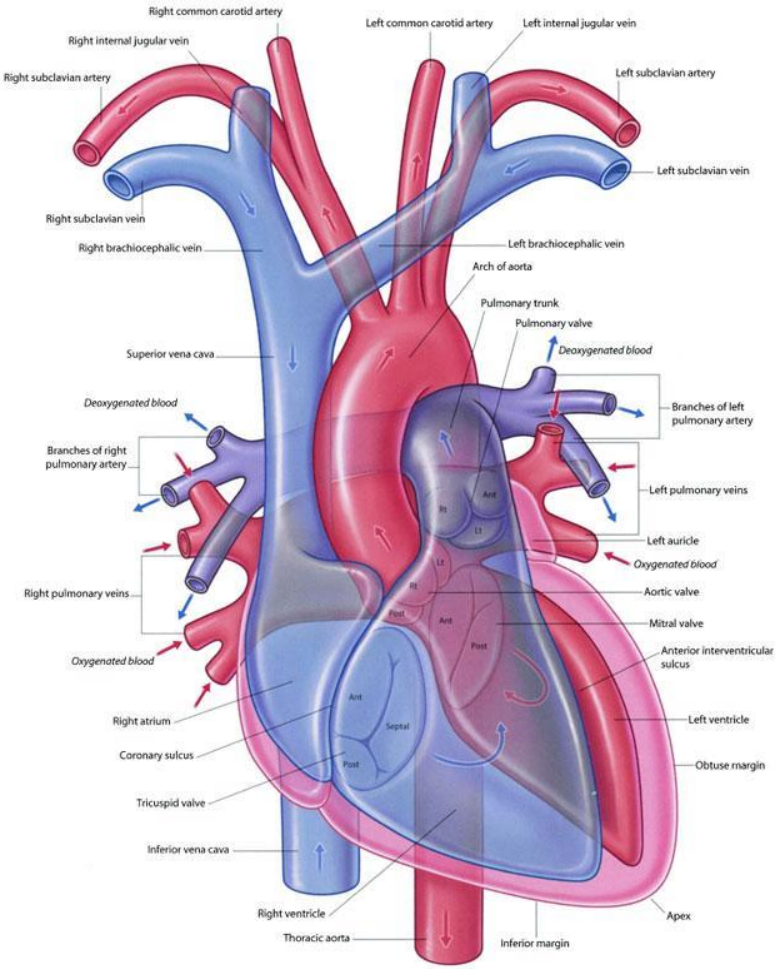

Cardiac chambers and direction of blood flow

(5) Venous hum

- Differentiate PDA murmur
  - “machinery”
  - loudest LUSB or L infraclavicular
  - associated bounding pulses or wide pulse pressure
  - XR: increased pulmonary markings, cardiomegaly

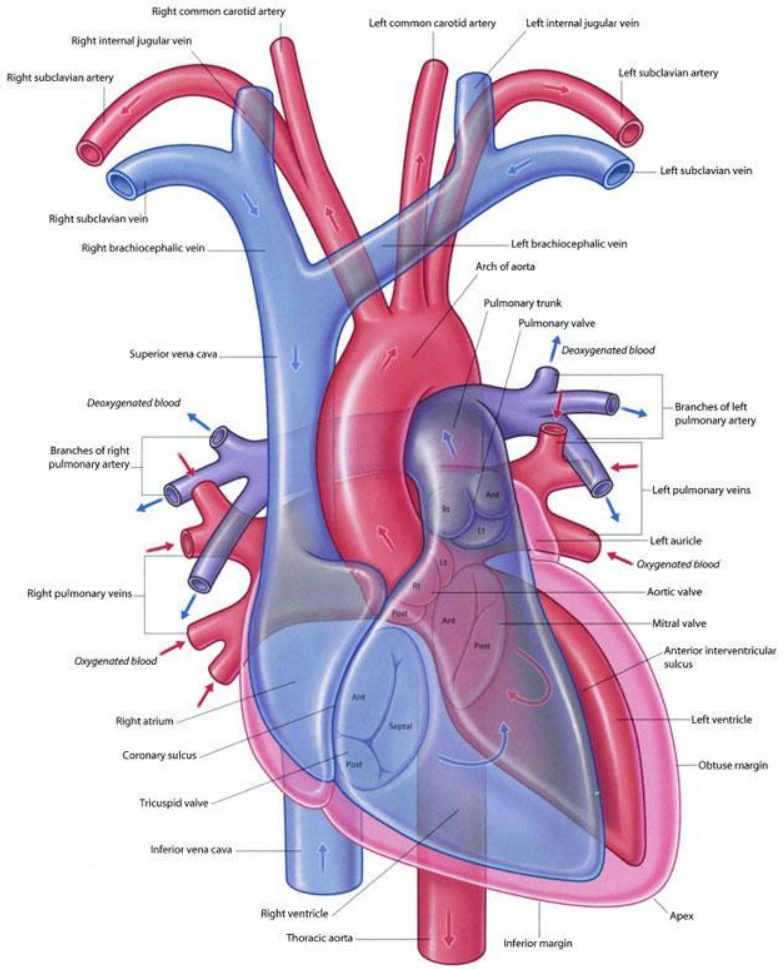

Cardiac chambers and direction of blood flow

Red flags

- symptomatic
  - respiratory symptoms
  - feeding difficulties
  - chest pain
  - syncope
- failure to thrive
- any pathologic murmur

Workup before referring

- Four-extremity blood pressures
- Pre- and post-ductal pulse oximetry
  - O2 saturation <93% in the lower extremities is abnormal
  - Clinical cyanosis is not seen until saturation <88%
- EKG
- CXR

Room:1
Loc:8

Vent. rate	110	BPM
PR interval	90	ms
QRS duration	52	ms
QT/QTc	316/428	ms
P-R-T axes	64 114 53	

** * Pediatric ECG analysis * **
Normal sinus rhythm
Right ventricular hypertrophy
Nonspecific T wave abnormality

Referred by: [redacted]

NOTES:

NOTES:

NOTES:

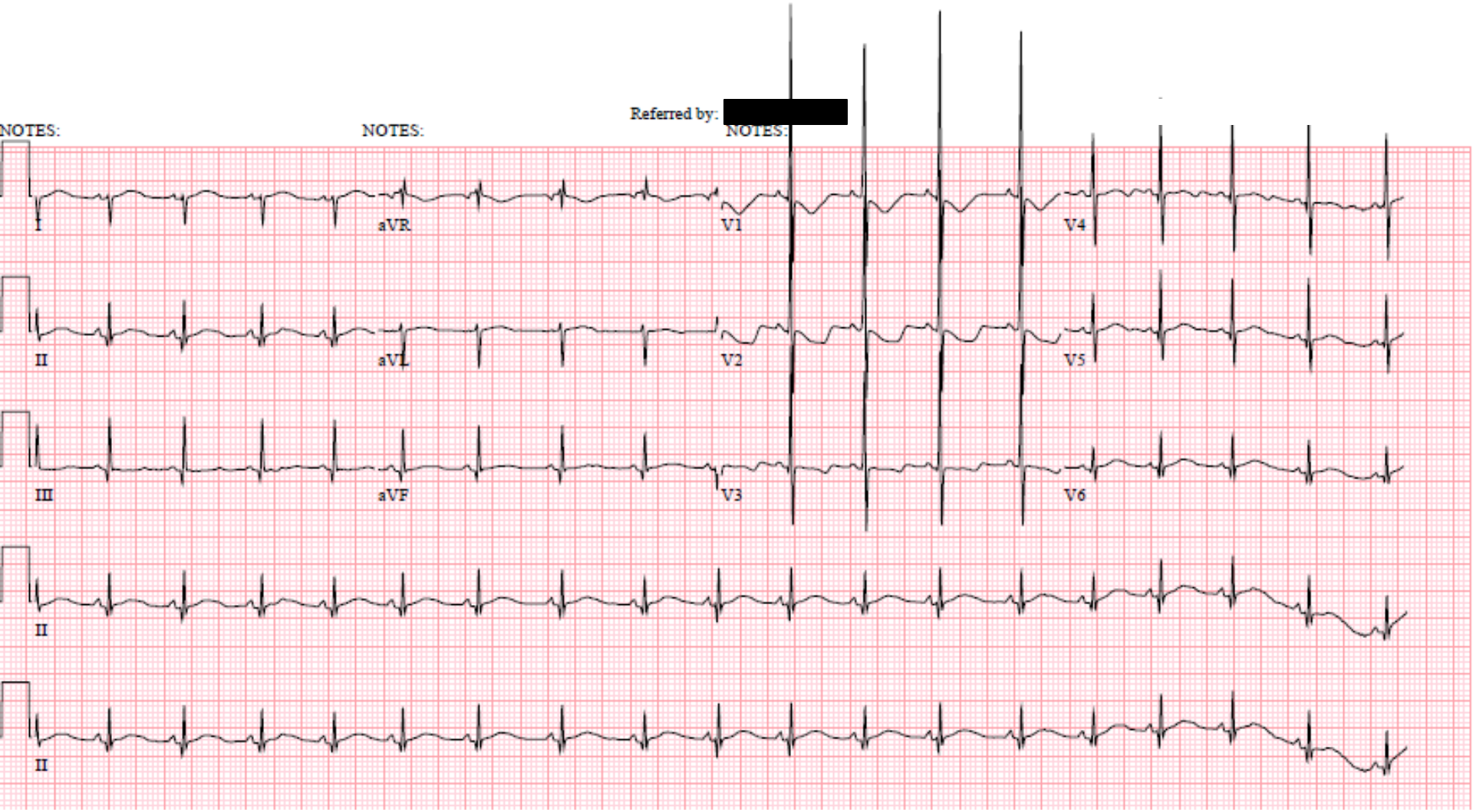

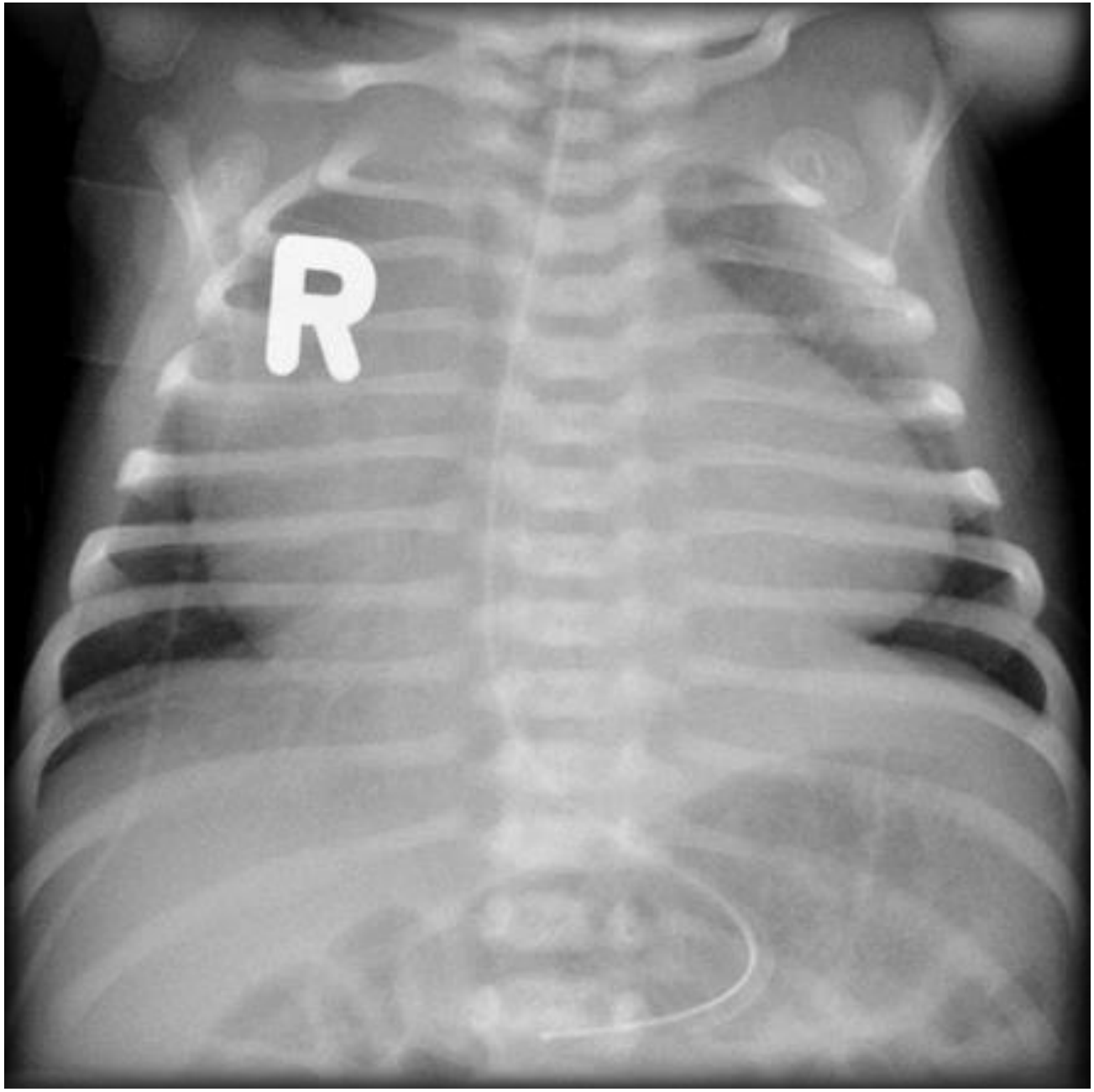
R

Review

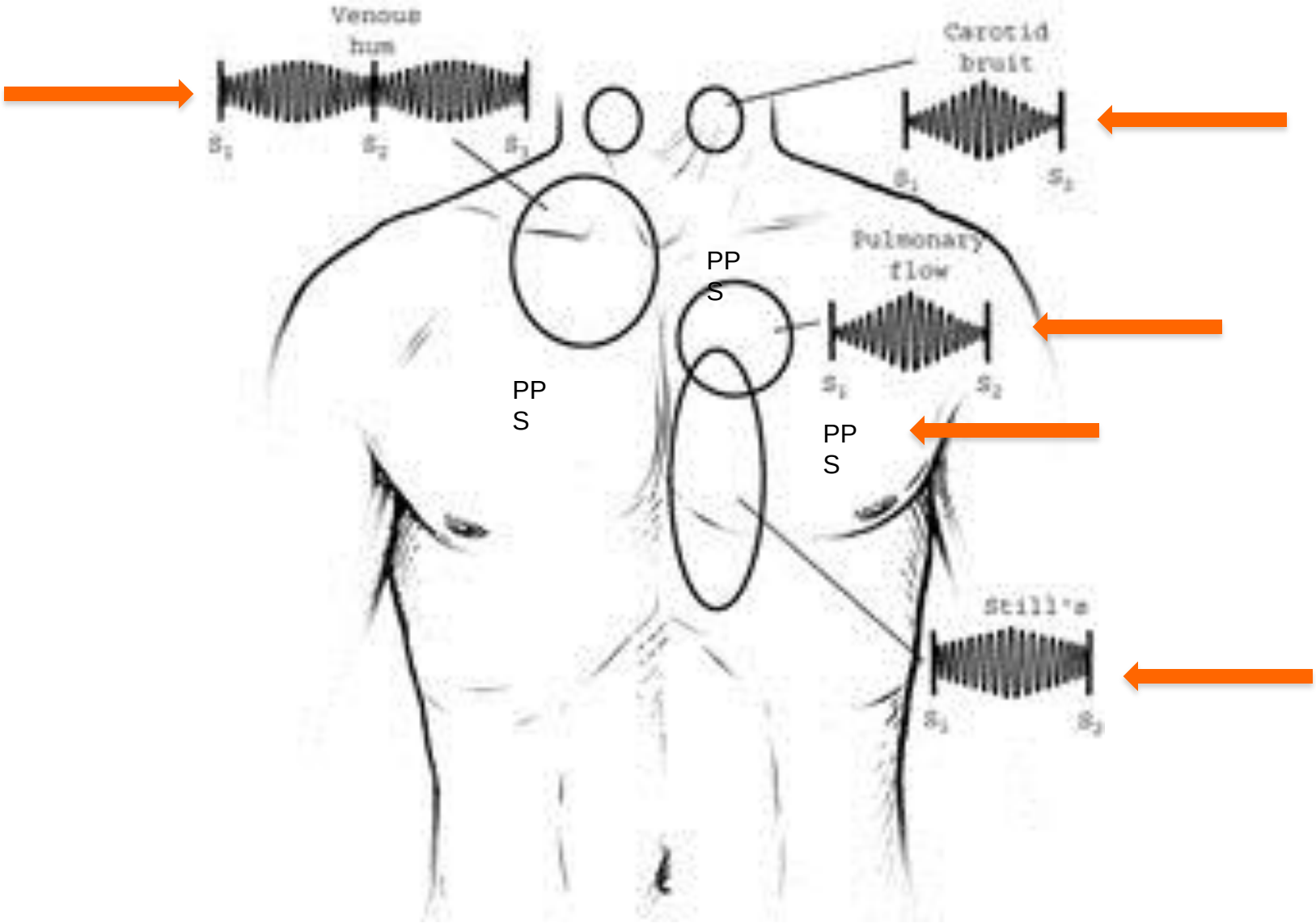

Discussion with parents

- describing a heart murmur
  - flow of blood moving through the heart
  - sound we hear with a stethoscope
- if clinical concerns
  - cannot see the heart's structure therefore will do some screening tests

Questions or Comments?

Video-conferencers:
Unmute your system to ask a question

Webcasters:
Type your question

Thank you!

for participating in today's

Pediatric Telehealth Rounds

Join us next time:

Hip Problems

with Dr. Ken Kontio

January 16, 2015

pedtelehealthrounds@cheo.on.ca