CHEO
child & youth

Pediatric Telehealth Rounds

Today's topic:

Hip Problems in Children

Speaker:

Dr. Ken Kontio

Jan 15, 2015

If you are connected by videoconference:

Please mute your system while the speaker is presenting.

Please feel free to ask questions!

By registering for today's event…

You will have had an opportunity to apply for **professional credits** or a **certificate of attendance**

You will receive an email with a link to today's **online evaluation**

You may also want to…

Visit our website to download **slides** and view **archived events**

Sign-up to our **distribution list** to receive our event notifications

Questions?
pedtelehealthrounds@cheo.on.ca

Disclosure

- **“I the author do not have an affiliation (financial or otherwise) with a pharmaceutical, medical device or communications organization”**

Objectives

By the end of the presentation, the participant will be able to, regarding the pediatric hip:

- Appreciate usual clinical presentation of DDH, Perthe's Disease and Slipped Capital Femoral Epiphysis:
- Understand clinical examination requirements to make the appropriate diagnosis for these conditions
- Know what imaging is most appropriate and the findings associated with these conditions
- Understand treatment principles and pitfalls for these conditions

Presentation Outline

- Slipped Capital femoral epiphysis (SCFE)
- Perthe's Disease (LCPD)
- Developmental dysplasia of the hip (DDH)

- Questions?

Slipped capital femoral epiphysis

SCFE

SCFE

- Most common cause of hip problems in adolescents
- Some are able to walk (stable) and some are not able to walk (unstable), <u>even with crutches</u>
  - Stable more common (main reason often missed)

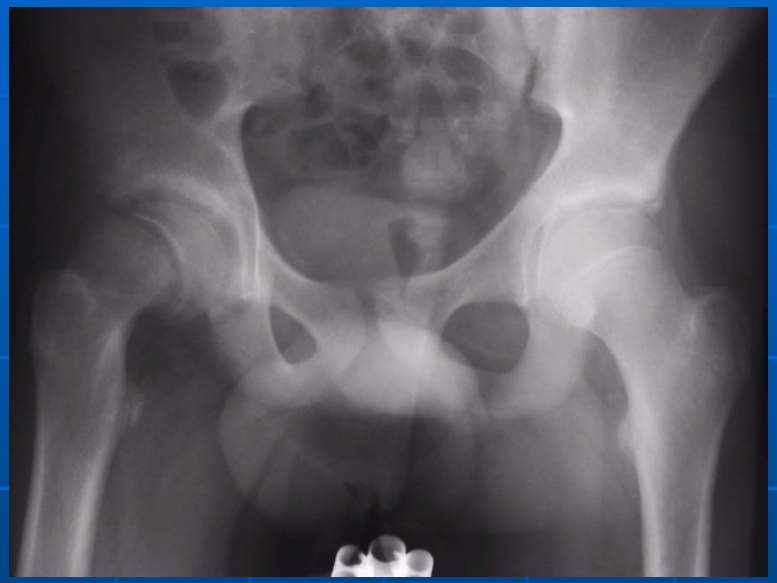

Making the Diagnosis

- HIGH index of suspicion is KEY to making the diagnosis
- Any “tween”/teen with funny walk , limp or vague groin, hip or THIGH pain needs assessment

Examination

- Physical findings:
- Remember femoral neck displacing and not femoral head
  - Often obese
  - Antalgic gait
  - Trendelenburg sign
  - Out-toed gait (ER foot)
  - Decreased IR
  - Obligatory external rotation with flexion hip
- 25% Bilateral !!

Workup-SCFE

- Xrays
  - AP and true or cross table lateral x-rays (frog view stresses hip and may displace in unstable setting)
  - Identify Kline's line on AP and LAT
  - "Pre-slip" is classic history or exam but x-ray normal except for possibly irregular physis
    - MRI

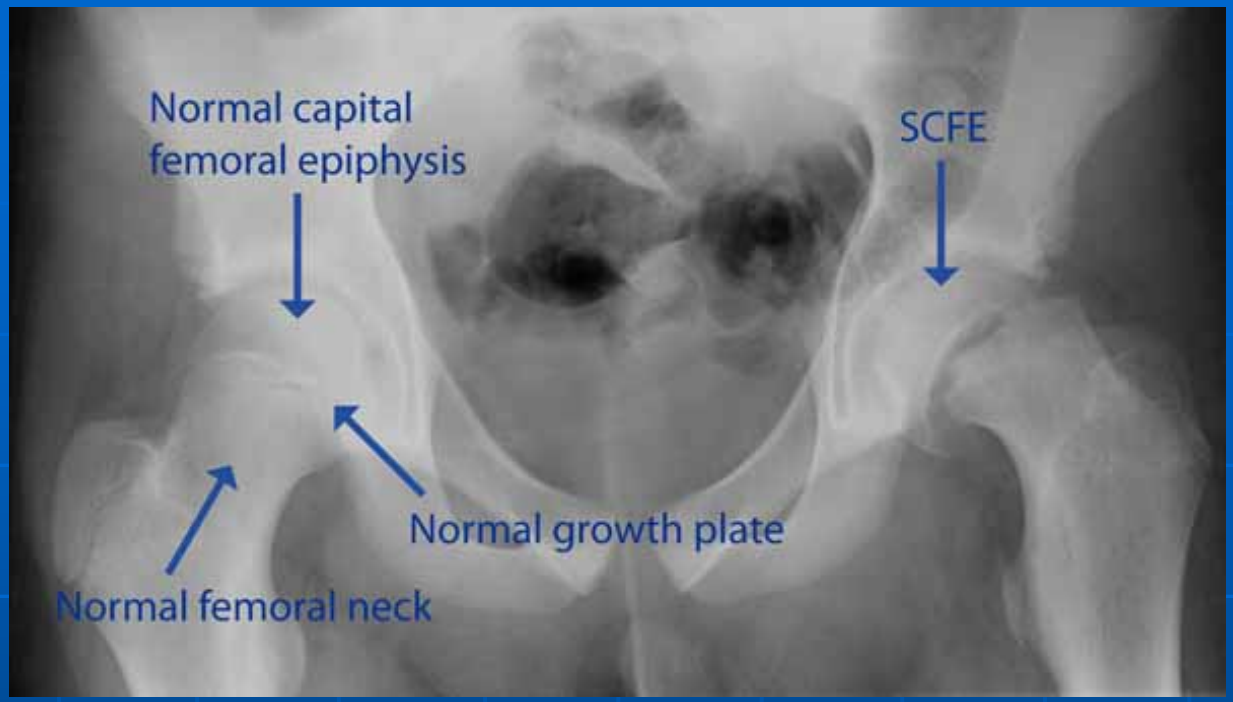

http://raymondliumd.com/Conditions_Slipped_Capital_Femoral_Epiphysis.html

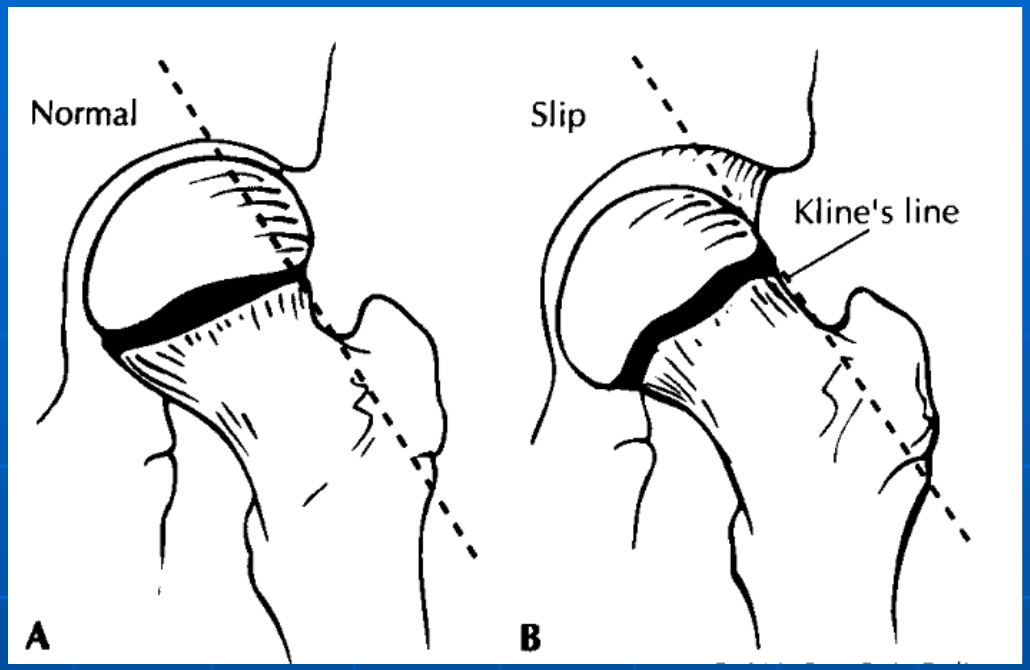

http://www.ped-rheum.com/content/7/1/10/figure/F2

http://www.merckmanuals.com/professional/multimedia/v1093820.html?Ref=s&ItemId=v1093820&RefID=/sec20/ch302/ch302f&Speed=256&Plugin=WMP

- Slipped Capital Femoral Epiphysis

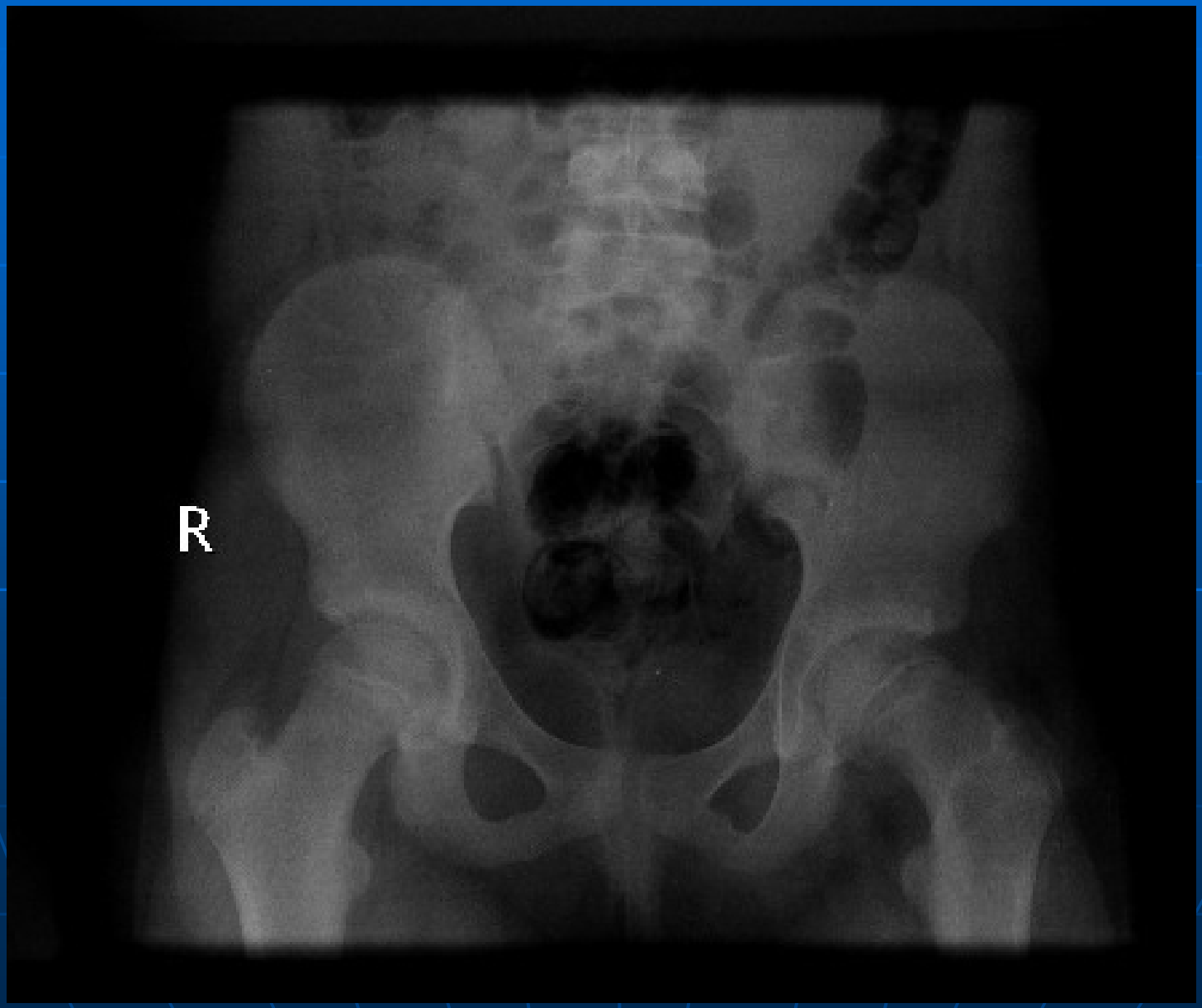

- Klein's Line – SCFE LEFT side

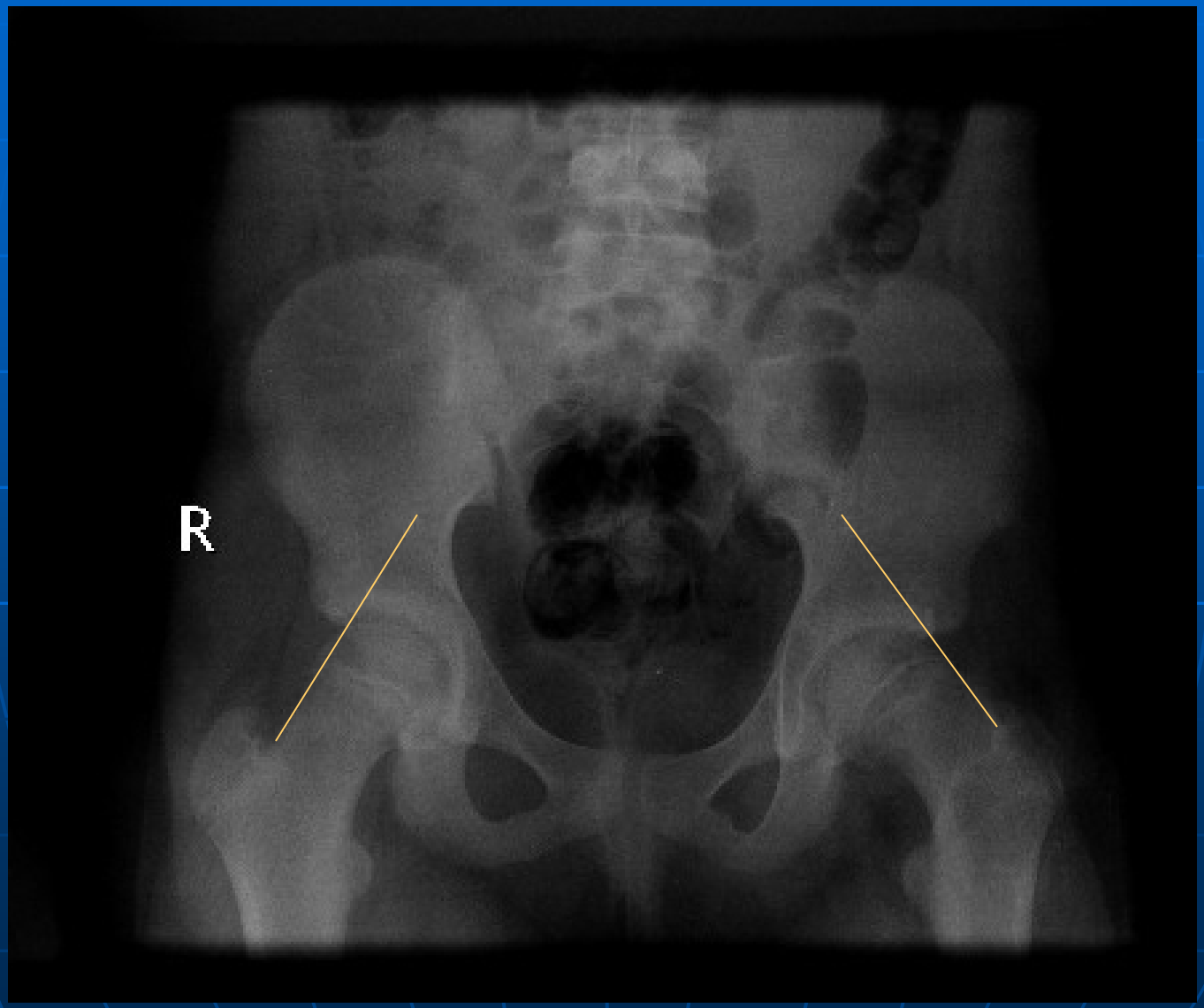

- Lateral view of SCFE (modified “Klein’s line”)

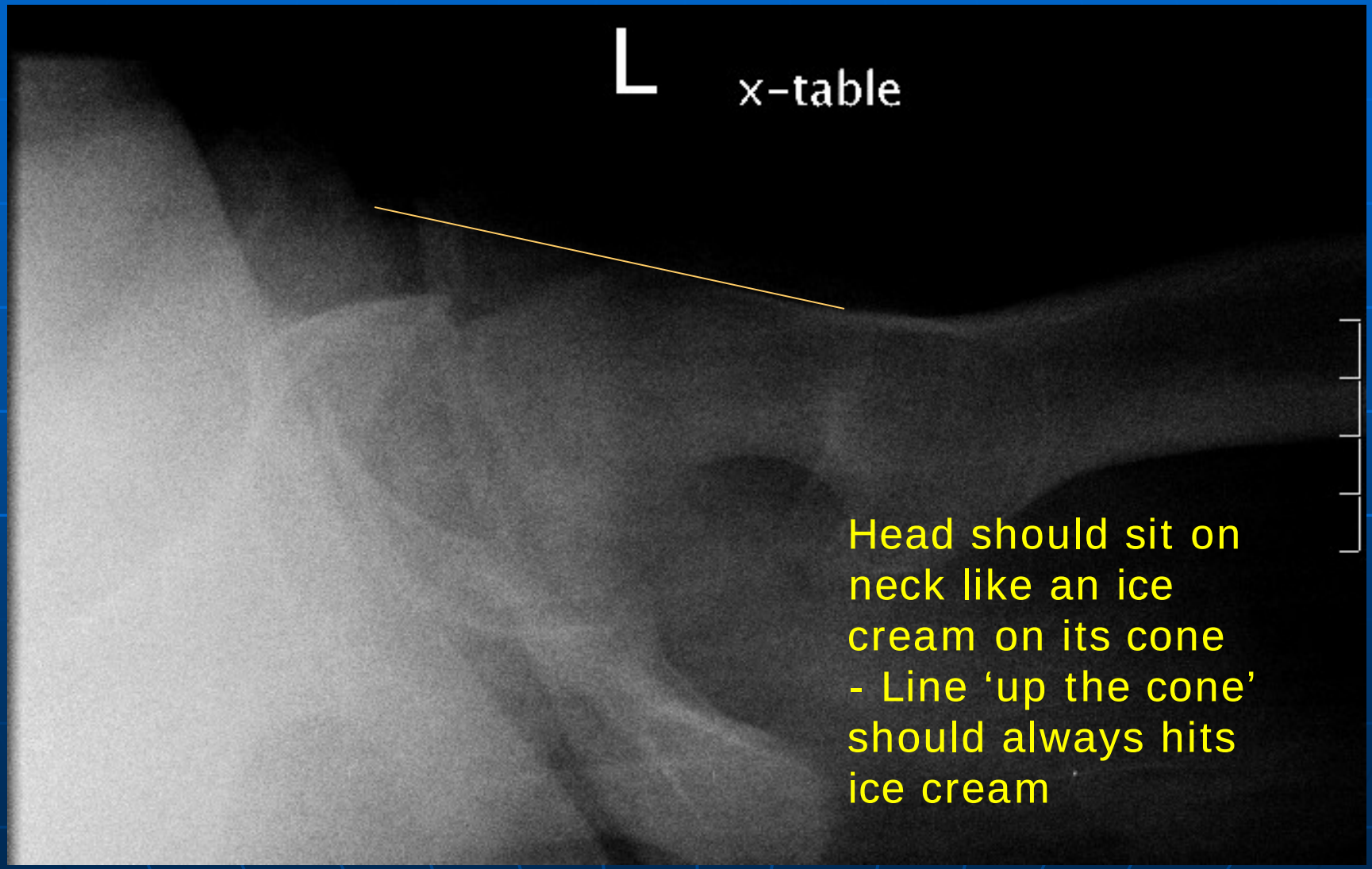

- Chronic changes (rounded)

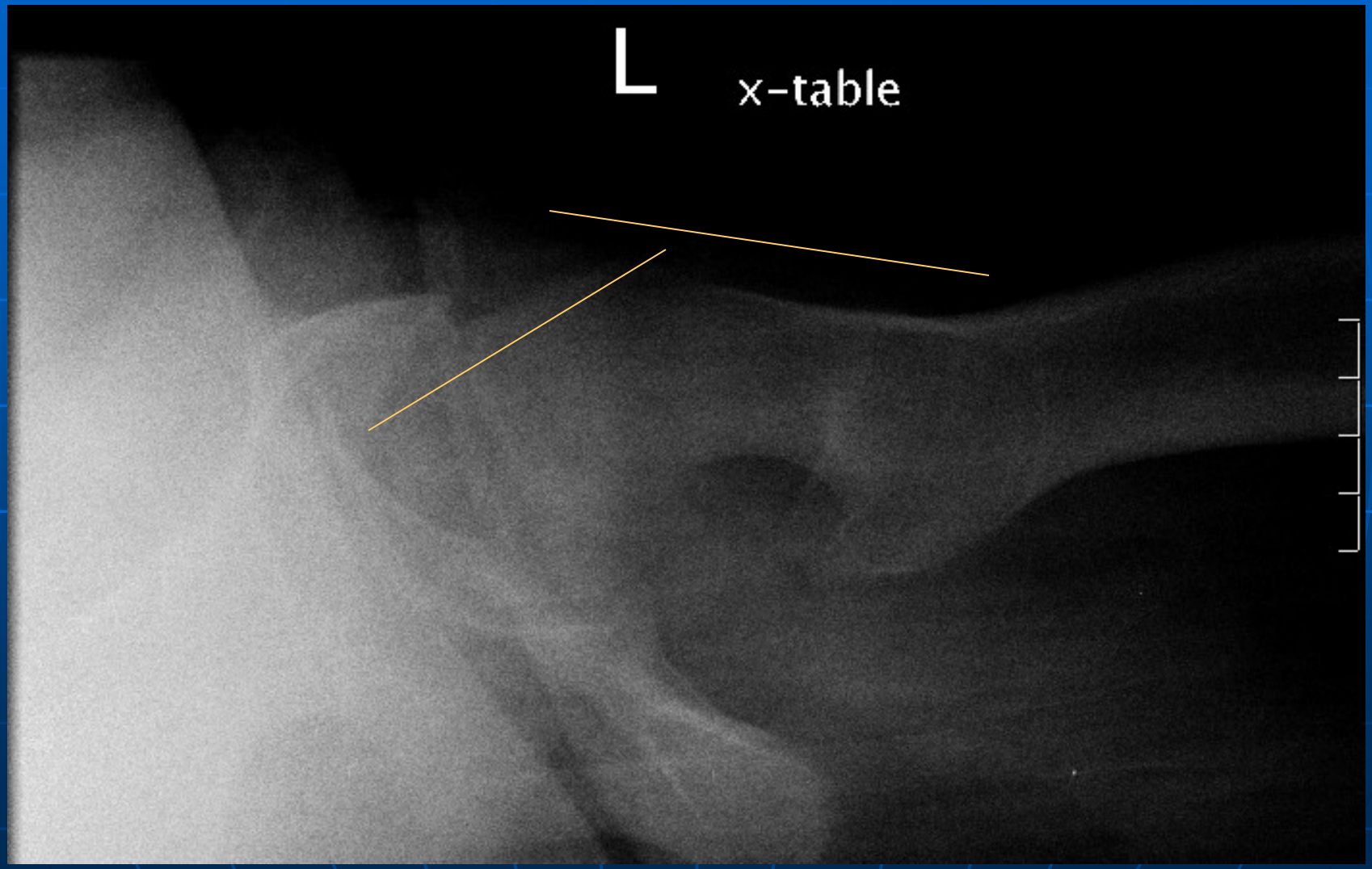

Bilateral disease or atypical presentation

- If not teen consider outliers (endocrine disorders, renal disease)
- NOTE;
  - Sick physis (growth plate) with widened lucency

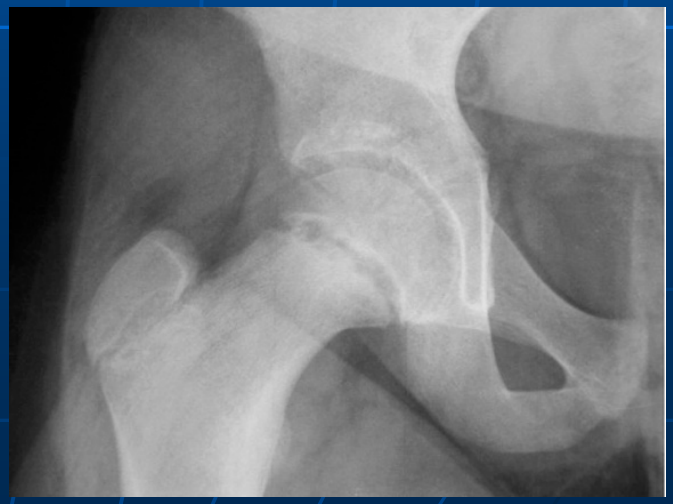

http://emedicine.medscape.com/article/413810-overview

So…What to do with them when you make the diagnosis

http://emedicine.medscape.com/article/413810-overview

SCFE

- Treatment
  - All need surgery
  - Make non-weight bearing immediately and refer
    - Admit to hospital, bedrest

  SURGERY
  - Screw fixation of slip
  - Protected weight bearing after surgery
  - Fusion in 9-12 months with minimal LLD
  - Activities when stable about 3 months post op
  - Screw stays in (very difficult to remove)

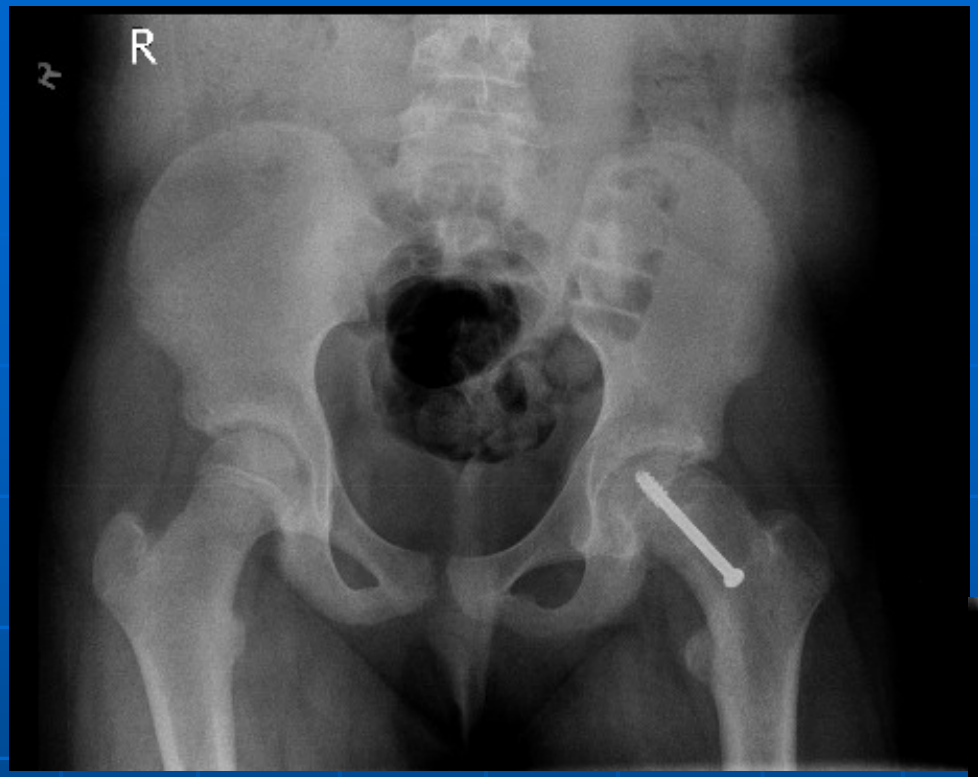

- SCFE fixation with screw

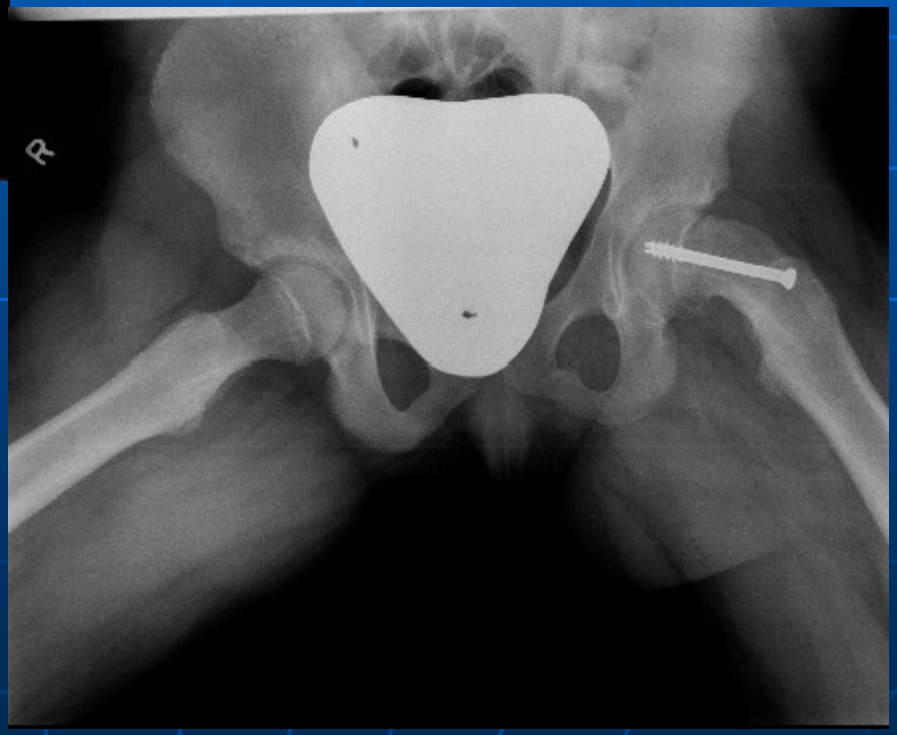

Growth plate needs to close for permanent protection from further slipping (8-10 months)

Would monitor Q6-12 weeks with xray
**in followup xrays always look at both hips for other side slip and AVN

Physis closing slowly

Patients instructed

"if other side starts to hurt at any time, seek medical / x-ray assessment immediately"

http://www.wheelessonline.com/ortho/treatment_scfe

Long term issues

- After healing residual deformity may cause hip impingement (FAI)
  - Restriction in flex and IR hip common
- Avascular Necrosis predisposes to early arthritis

https://mayapedia.me/posts/evaluation-and-management-of-slipped-capital-femoral/

SCFE summary

- High index of suspicion KEY to Dx
- If good clinical history, look very carefully for x-ray changes
  - Irregular physis without slip still Dx
  - Often missed in ER settings
  - Inappropriately interpreted films
- Key is to avoid further slip and AVN
  - Unstable group very high risk of AVN

Perthe’s Disease (Legg-Calves-Perthe’s)

Perthe's Disease

- Idiopathic osteonecrosis of the proximal femoral epiphysis
- "blood supply problem to the femoral head (ball of the hip ball-and-socket joint)"
  - Cause unknown (theories)
    - coagulation abnormalities
    - Smoking
    - Nutritional deficits

Perthe's Disease

- Incidence:
  - Perthes' disease is one of the most common hip disorders in young children, occurring in approximately 5.5 of 100,000 children per year.
  - The lifetime risk of a child developing the disease is about 1 per 1,200 individuals.
  - Boys are affected about 3-5 times more often than girls.
  - White northern Europeans appear to be affected more frequently than other races, though there is a paucity of reliable epidemiology in the southern hemisphere
  - Anectodally we have a lot of patients from northern Canada and Inuit population (NU)
    - NU pop 40,000 and 35% kids (14, 100) and we have a few cases per year (study discussion)

LCPD (Idiopathic Osteonecrosis)

- Classically hip concern in child 4-8 years
- Commonly knee/thigh pain as presenting complaint
  - If knee/thigh pain always think about hip pathology
- Painless limp early ⇒ pain and decreased ROM occur as disease progresses (abduction hip especially)

Perthes

- X-Ray
  - AP / Frog LAT hips looking for
    - subchondral lucencies (cresent sign)
    - collapse femoral epiphysis
  - Unilateral or mixed stage bilateral

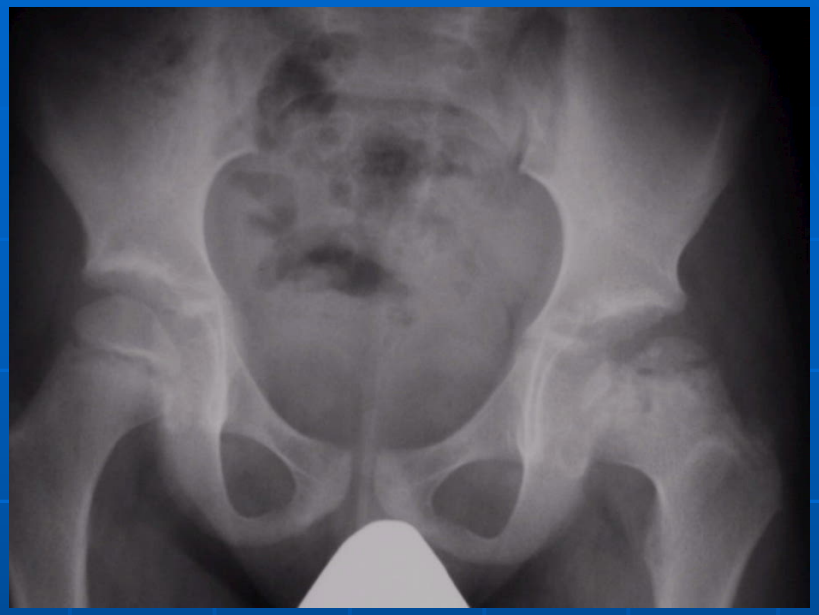

- Subtle differences in the hips? (right sore)

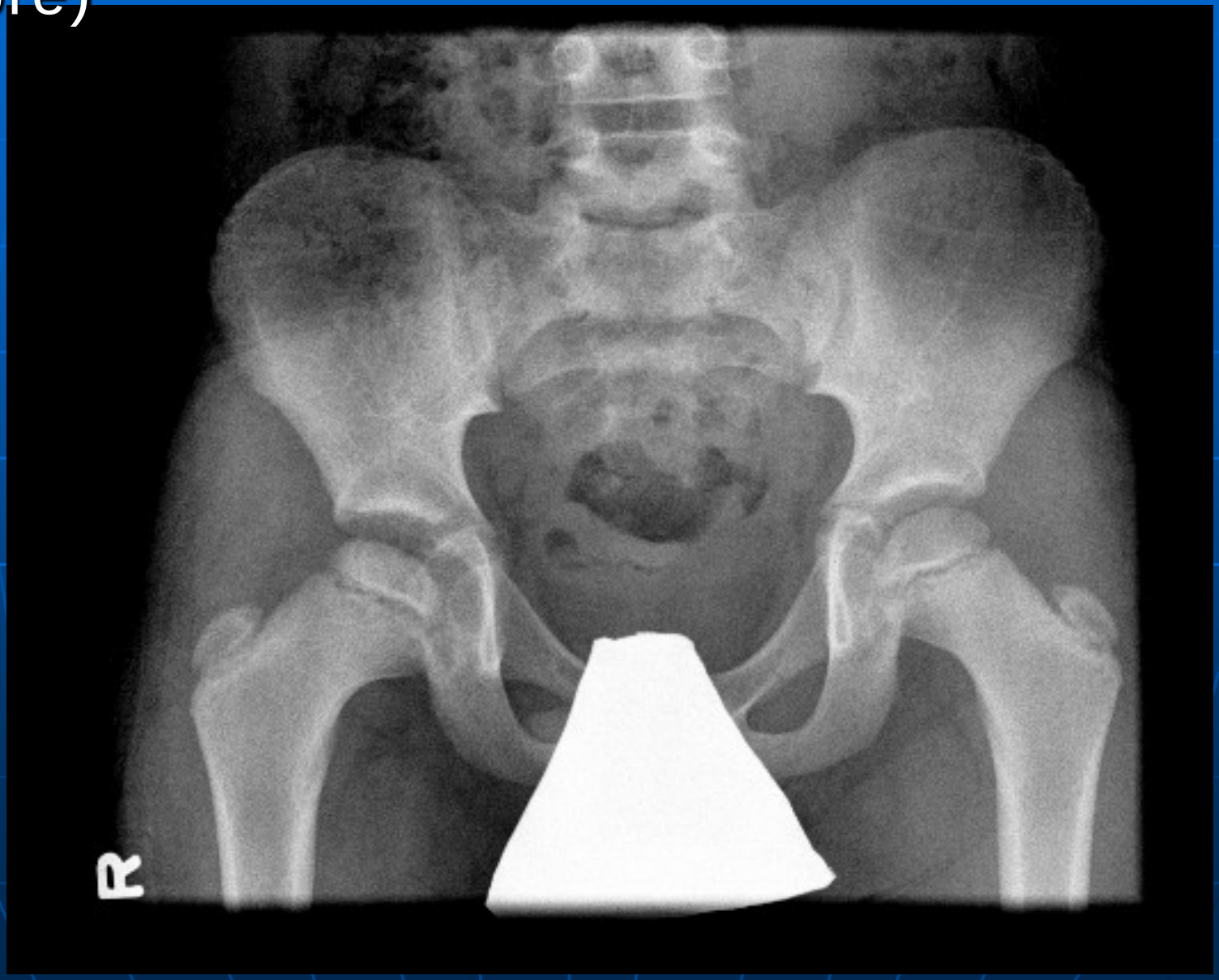

- Frog lateral (lucencies in the epiphysis?)

- Legg-Calves-Perthes disease

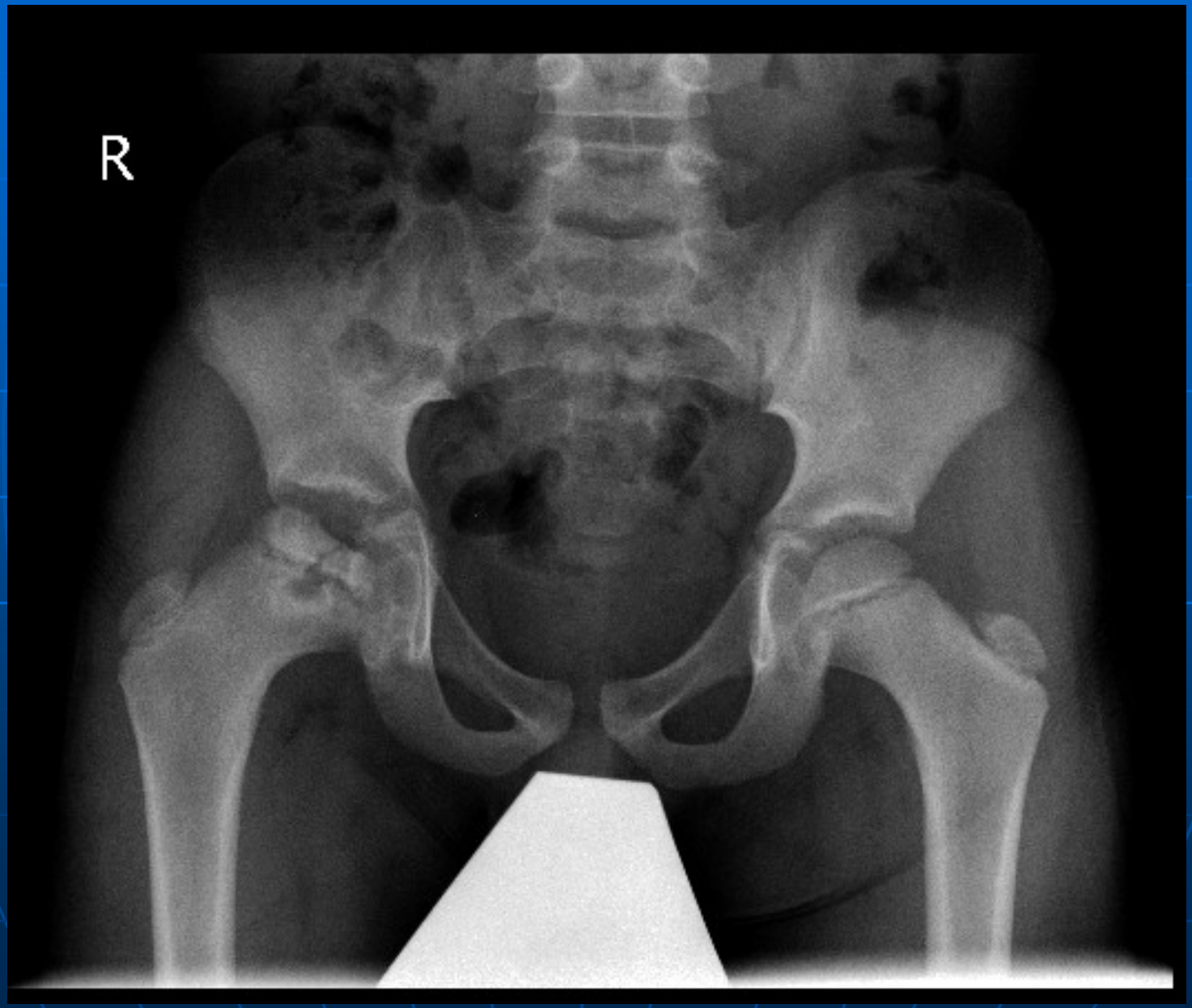

- Frog lateral – Perthe's Disease
  - Note lucencies in epiphysis and metaphysis

Stages of disease

Stage 1 Avascular necrosis → Stage 2 Fragmentation/Resorption → Stage 3 Re-ossification

- Biological process
  - Blood supply lost (bone normal to rel. dense-initial stage)
  - Body recognizes dead bone and starts absorbing (bone lucency- fragmentation stage)
  - Bone starts to be laid down (new densities- reossification stage)
  - Bone reshapes to final form (hip matches head amap)(mature looking bone - remodelling stage)

http://www.tsrhc.org/Perthes-Disease

Outcomes

The x-ray outcome at the healed stage depends on 3 main factors:

- Age at onset of the disease. The onset of Perthes before age 6 is better than after age 6. The onset of Perthes after age 9 is generally associated with a poor outcome.
- Amount of femoral head involvement. The outcome is poorer if more than 50% of the femoral head is affected by the death of the bone.
- Development of certain radiographic changes during the fragmentation stage. A decrease in the height of the lateral part of the femoral head during the fragmentation stage will affect outcome. For example, a poor outcome is expected if the head loses more than 50% of its original height. These radiographic changes are characterized by lateral pillar classifications. Other x-ray changes associated with poor outcome are moderate to severe extrusion of the femoral head and growth disturbance of the growth plate below the femoral head.

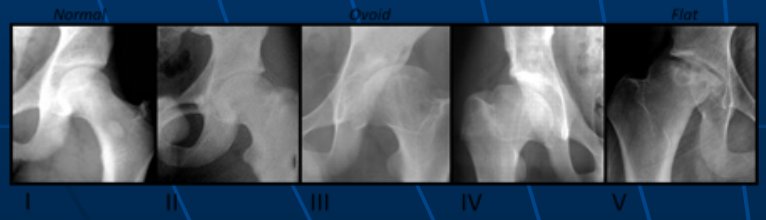

http://www.tsrhc.org/Perthes-Disease

What do we deal with as clinicians?

The clinical problems associated with Perthes disease can be divided into two main types:

1. Those problems that occur before reaching the healed stage of Perthe's-fragmentation 6-18 months)
   - Pain and limping due to hip joint inflammation
   - Femoral head extrusion and collapse
   - Some loss of hip joint flexibility due to pain, inflammation, or femoral head flattening
   - A mild shortening of the affected leg of usually ½ inch or less.
2. Those problems that occur after reaching the healed stage of Perthe's:
   - Possible decrease in hip joint flexibility due to a permanent change in the shape of the femoral head, an enlarged femoral head, and a shortened femoral neck from growth disturbances.
   - Pain during daily or sports activities due to femoral head impingement (i.e. the deformed, enlarged femoral head is bumping into a part of the socket)
   - Pain and limping due to early arthritis. A deformed femoral head that does not fit well into the socket is more prone to wear-and-tear.

http://www.tsrhc.org/Perthes-Disease

Treatment

- Tx
  - Depending on age and stage of disease (Nat. Hx 2-3 yrs)
  - Activity modification,Physiotherapy and anti-inflammatory medications, for maintenance of ROM, is the mainstay of treatment
- Goal is to protect “soft head” while disease runs its course naturally

Treatment -conservative

- Restriction of long walks, sports, running, and jumping activities
- • Range of motion exercises with focus on hip abduction and rotation.
- • Bed rest for few days if hip joint flexibility is severely limited
- • Weight relief of the affect leg using crutches, walker, or wheelchair if x-ray changes associated with poor outcome are seen
- • Petrie casts (long leg casts with abduction bar) and abduction bracing if hip is unresponsive to above options or if a patient presents at a later stage of Perthes with hip joint stiffness.

Treatment

- A-frame casts (Petrie casts)
  - Intermittantly to get and maintain ABDuction
- Bracing has fallen out of favour

Surgery?

- Controversial
  - Minor surgery (adductor release) with casting is common
  - Certain groups MAY benefit
    - Less than 50%
    - early fragmentation
    - 6-8 yrs old

LCPD Summary

- Early detection in limping child with thigh and knee pain ALWAYS examine hips (xray if abnormal)
- Treatment is mainly conservative but early referral to ortho useful to catch subset that may benefit
- Long term issues not uncommon (restricted ROM and LLD as adult)
- Arthritis issue as early adults (40's onwards)

Developmental Dysplasia of the Hip

Case 1

- Emma, a 1.5 month old baby girl is found to have a mild asymmetry to her thigh skin folds. Pregnancy and birth history are normal Hip exam is normal. There is a vague family history of some hip problems as a child in a distant uncle.

- What would you do for this child?

Risk Factors for DDH

- Classically history of 5 “F’s”
  - Presentation – “Frank” breech
  - Sex - Female
  - Birth order – First born
  - FHx – quite important, 20%+.
  - LeFt hip more than right.

Clicking hips

- Risk Factors for Developmental dysplasia of the hip: Meta-Analysis
  - *De Hundt et al., Eur J Obstet Gynecol Reprod Biol 2012 Nov;165(1):8-17*

- 1.49 million children (26 cohort,4 case-control studies)

- Breech delivery (OR 5.7, 95% CI 4.4-7.4)
- Female sex (OR 3.8, 95% CI 3.8-5.6)
- Positive family history (OR 4.8, 95% CI 2.8-8.2)
- Clicking hips on exam (OR 8.6, 95% CI 4.5-16.6)

- **Clicks not defined (minor at hip of knee or audible??)**

- **Currently minor "subtle" clicks not felt to be important (tendon's snapping etc)**

Universal screening of babies for DDH

- Controversial internationally
- North American stance:
  - To Screen or Not to Screen? A Decision Analysis of the Utility of Screening for Developmental Dysplasia of the Hip

Susan T.Mahan et al. *JBJS 2009 91(7),1705-19*

- screen all neonates for hip dysplasia with an abnormal physical examination (instability on testing)
- use elective ultrasonography **selectively** for infants who are at high risk *(Breech presentation, Family History).*

Case 2

- Amelie, a 2 week old baby girl, presents to your office for first postnatal visit. She was born of a C-Section for breech presentation, and has a family history (mother treated) for DDH.

- What examination would you carry out on the hips? Is age important?

DDH - Exam

- Galeazzi Sign
  - Hips and knees bent
  - Feet or heels flat on bed
  - Knee height observed for symmetry
  - Lower on abnormal side (dislocated side)

DDH - Exam

- Thigh folds
  - Observe legs extended and beside one other
  - Either anterior or posterior (preferred)
  - « Abnormal side » has extra folds

www.mymommyconfessions

Special tests – DDH

(Note – unreliable > 3-6 months old)

- Ortolani Test
- `Sign of entry`
  - Reduction test for *dislocated* hip
  - Child supine with hips and knees flexed at right angles
  - Long finger on greater trochanter
  - Thigh lifted and abducted
  - ¨ + ¨ if head of femur felt to slip back into acetabulum

Special tests – DDH

- Barlow Test
- `Sign of exit`
  - Dislocation test for reduced but *dislocatable* hip
  - Child supine with hips and knees at right angles
  - Thighs adducted and posterior telescoping force applied
  - ¨ + ¨ if head of femur felt to slip out of acetabulum
  - Important to reduce if ¨ + ¨

AGE IMPORTANT?

- Ortolani and Barlow tests are only possible on babies due to ligament laxity
- As baby matures, laxity will be lost
- Those that are in, stay in, those that are dislocated, stay dislocated
  - These tests (ORT/BAR) not useful after 3-4 months accordingly

- MOST sensitive sign for dislocated hip after 3-4 months would be DECREASED ABDuction
  - Asymmetrical abduction if unilateral
  - Careful exam watching pelvis tilt important
  - Ensure pelvis always level with checking ABDuction

Case 3

- David a 1 week old with negative family history for DDH and a vertex presentation comes to you for post-natal assessment
- Examination shows:
  - Positive Barlow ? “GLIDE” more than a sense of full “dislocation”
  - Negative Ortolani (hmmm…could it be positive with a positive Barlow?)
- What to do for this child?

Barlow "+" exams

- Very Common in newborns for 1-3 weeks post delivery
  - Laxity felt to be due to maternal estrogens in tissues
- Will settle by 3 weeks generally and felt to be a NORMAL finding

- Treatment: if normalizes no Tx needed.
- Imaging only if indicated on history (risk factors such as Fam. Hx and breech presentation)

Case 4

- Lauren, a 4 week old infant is brought to your office for a clunk felt while diaper changing
- Examination reveals , indeed, an Ortolani positive hip on the left side

- What to do now?

All dislocated hips NEED Treatment

Pavlik harness application with repeat ultrasound in 1-3 weeks

- Treatment often dictated by examination alone (current position and future development independent)
  - Examination can be positive for laxity (Barlow). Watch clinically for stabilization in next week (physiologic laxity first 1-3 weeks)
  - If abnormal after 3-4 weeks of age, start brace treatment

- This hip is dislocated!
- Goal is reduction confirmed by imaging in <u>first 3 weeks</u> of Pavlik harness <u>treatment</u>
  - If not in by then <u>abandon</u> harness and move to CR / Cast
    - No treatment BETTER than BAD treatment
  - Repeat Ultrasound 3-4 months to confirm development of socket

DDH - Ultrasound

- Safe, non-invasive hip imaging
- Assesses structures not visible on radiographs
- More sensitive than clinical exam: can be used in conjunction with P/E for dynamic examination
- Neonatal U/S has higher false positive rate
- U/S after 6 weeks is more accurate

DDH - Ultrasound

- Graf et al introduced U/S to clinical practice
- Measurement of bony and cartilagenous components to assess formation of the acetabulum (hip socket)
- Alpha angle = osseous coverage femoral head (N>60 degrees)
- Beta angle = cartilagenous coverage femoral head (N<77 degrees)
- Very operator dependent test (high volume needed for learning curve)

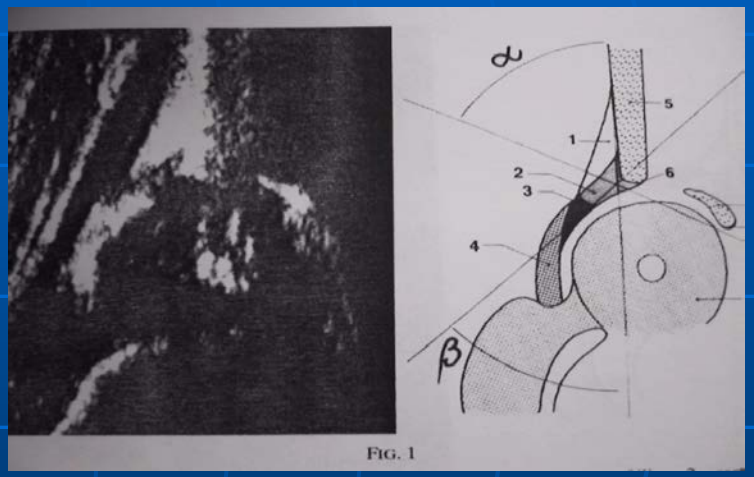

Case 5

- A 6 month old child is brought to you for assessment of possible LLD and decreased ROM. You confirm a dislocated left hip (decreased abduction, Galleazi +, Xray confirmation)
- What are the treatment goals and options?
- Would age at presentation make a difference? (6-18 months?)

DDH - Radioghraph

- Traditional means of investigation
- Detail limited by extent of ossification of proximal femur
- Femoral head ossification may be as late as 6 months and usually delayed in dysplastic hips

DDH - Radiograph

- Special lines used to help interpret findings
- AI < 30 degrees and head in inner lower quadrant = normal

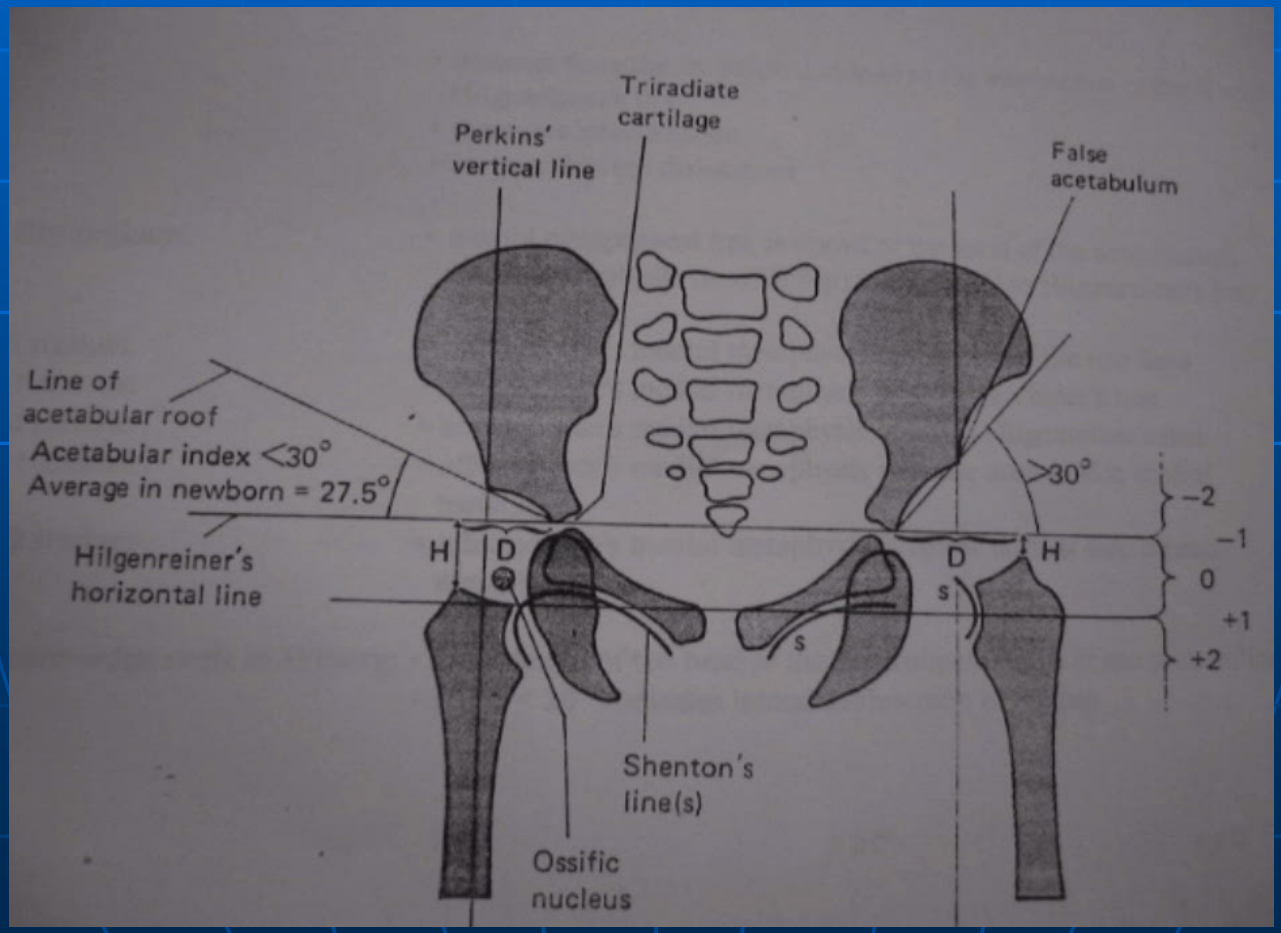

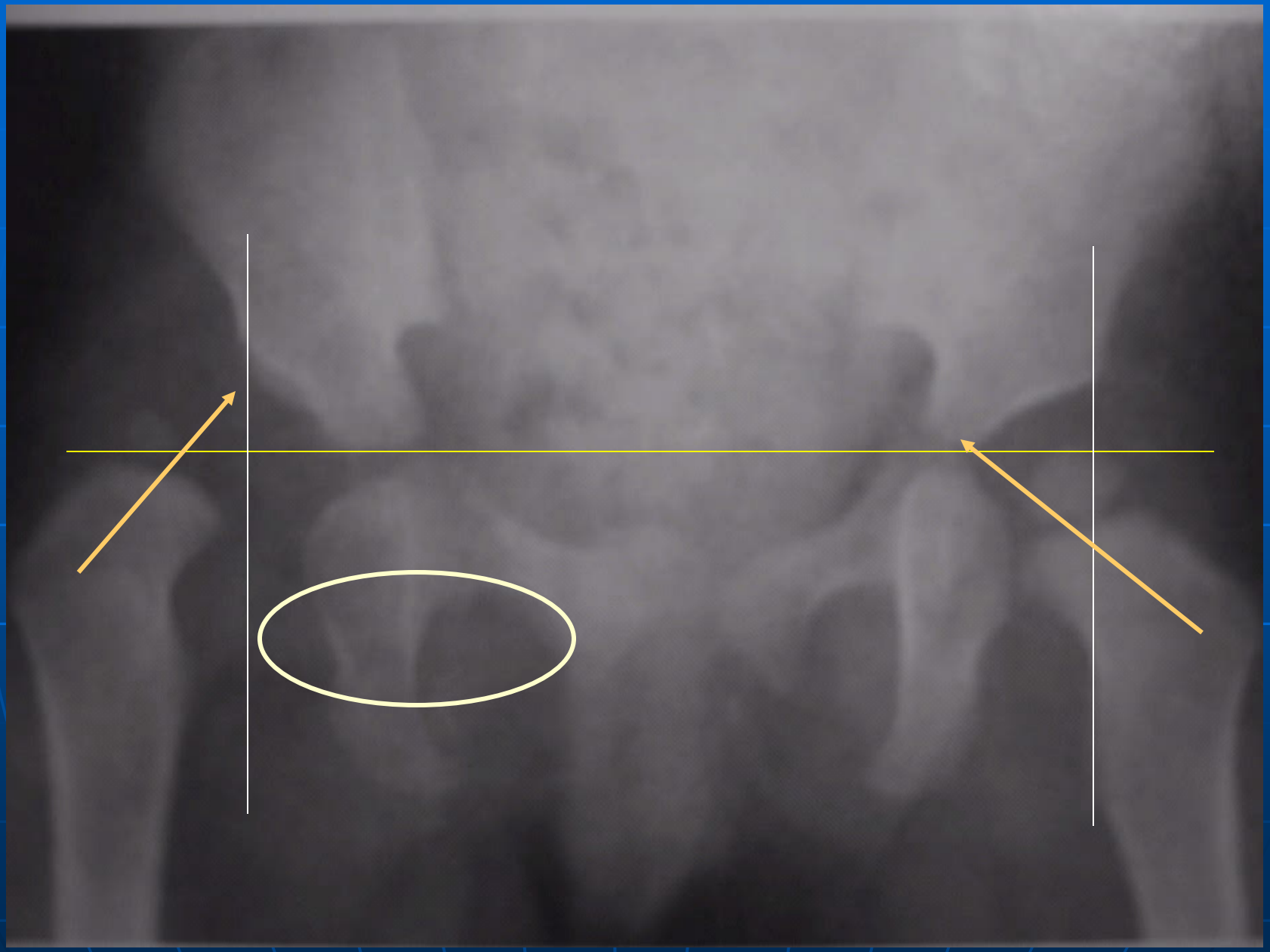

DDH - Treatment

- Goals of treatment:

1. Obtain concentric reduction of hip

2. Maintain concentric reduction of hip to promote remodelling of abnormal hip joint, specifically the acetabulum

3. Avoid complications

DDH – Treatment (options)

- Do nothing
  - For questionable findings or routine ‘click’ with normal exam
  - Close follow-up is recommended
- Double diaper
  - Traditional method of directing head into socket
  - Not uniform in application and limited control achievable
  - Appropriate in the interim while awaiting to fit into harness (premature infants)
    - Treating MOM and DAD more than baby?

DDH – Treatment (options)

- Pavlik Harness
  - Most common form of treatment
  - Begun ASAP and used for: child's age X 2 + one month + weaning (4 to 8 weeks)
  - Exam or U/S should confirm reduction within 2 weeks and we would expect acetabular index to decrease by 1.6 degrees / month in successful treatment (XR)
  - Ideal position:
    - 100-110 degrees flexion
    - 30-60 degrees abduction (safe zone)

DDH – Treatment (options)

- Closed reduction
  - For hips which will not reduce with Pavlik harness use by two weeks or children too old for Pavlik harness ~ 6 mo-1year old
  - Often combined with percutaneous soft tissue releases
  - Casting and CT scan for post-operative confirmation

- Open reduction
  - For failure of closed reduction
  - Includes capsular tightening and possible femoral osteotomy
  - For much older children, with poorly developed acetabuli, pelvic osteotomy also may be needed

DDH – Treatment guidelines

- Birth – 6 mo
  - Usually Pavlik harness but occassionally CR needed
- 6 mo – 18 mo
  - Traction (controversial) pre-reduction
  - Closed reduction (non forceful) or open reduction
- 18 mo – 3 years
  - Open reduction with soft tissue releases +/- osteotomy
- Greater than 3 years
  - Open reduction with osteotomy
  - >8 years, unilateral dislocation = do not reduce
  - >5 years, bilateral dislocation = do not reduce

DDH - Complications

- AVN – Avascular Necrosis
  - Even with optimal treatment, risk remains about 0 -10%
  - Affects total proximal femur: early in development it shares common growth plate
  - May lead to growth disturbances such as coxa magna, breva, valga
  - Risk reduced by avoiding forceful reduction and extremes of ROM

DDH - complications

- Early arthritis
  - Generally good results with well formed hips
  - Large percentage will have residual mild dysplasia leading to OA at 50-60 yrs of age
  - Follow-up after treatment recommended to maturity

Treatment of DDH after 6-9 months of age

- Pavlik harness useful while it fits up to about 8-12 months of age
- If still dysplastic, abduction orthoses used for sleep timeframes
  - Yearly follow-ups with AP and FROG lateral hips
  - Assessment of the Acetabular Index used with plan xrays

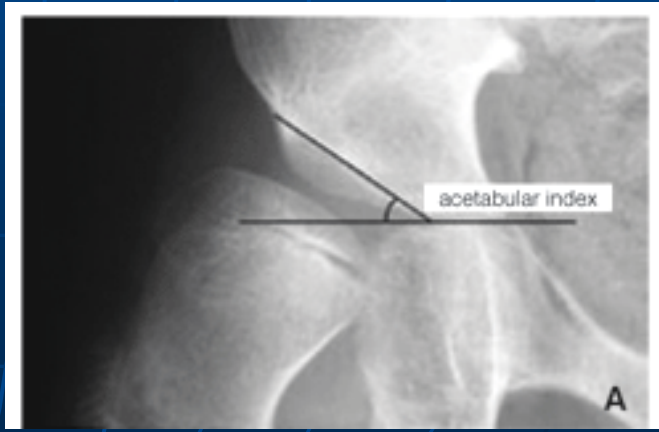

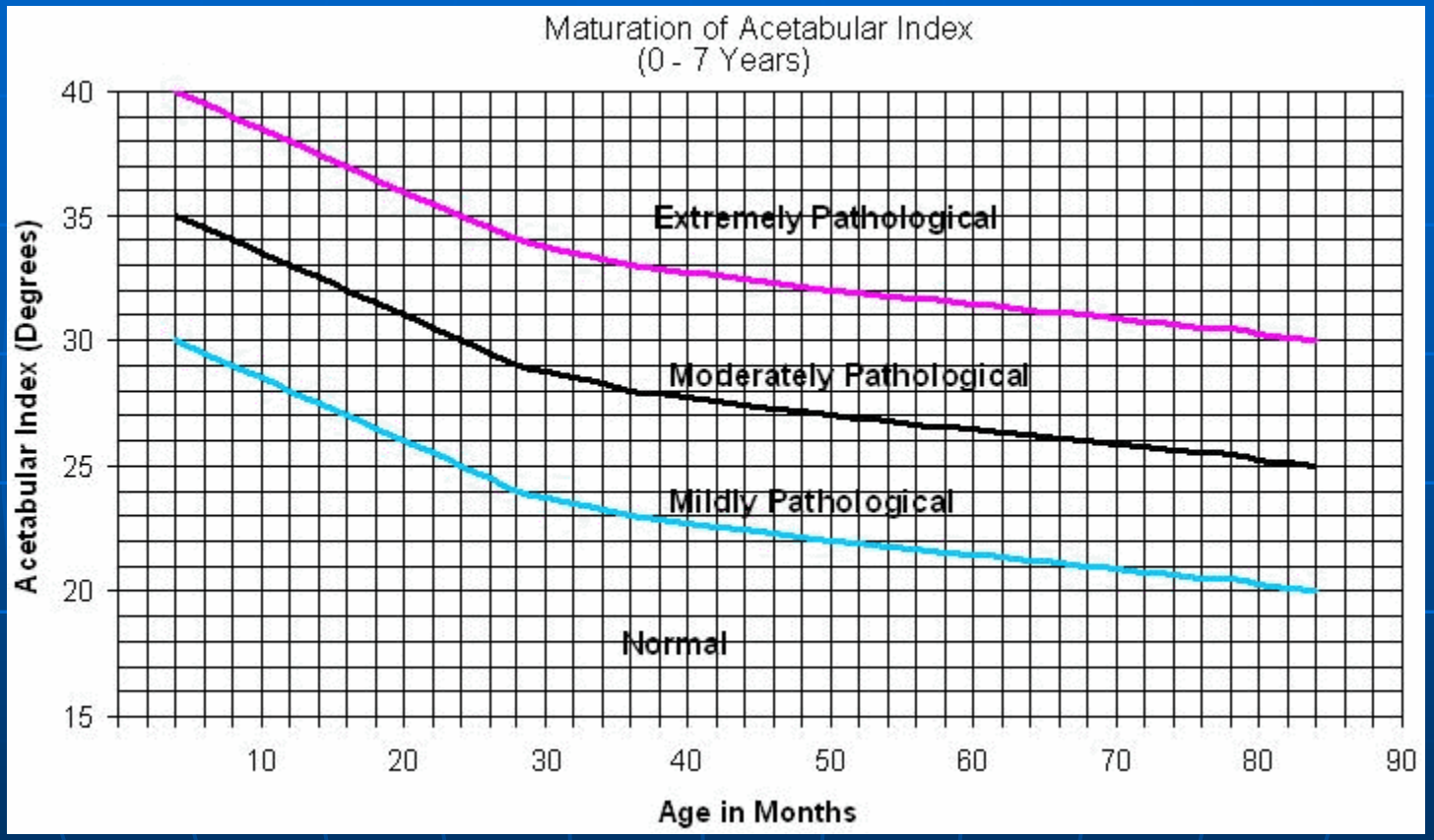

http://www.dr-toennis.de/pages/vortraege/evaluation-of-normal-values-of-the-hip.php

Indications for Surgery – Late persistent DDH

1. Subluxation the of the hip joint
2. No progress of acetabular development for 18-24 months consecutively under active treatment
   1. Acetabular index doesn't decrease for 2 yearly visits
3. Significant dysplasia still present at age 4-5 yrs
   1. If surgery is to be done, having it completed with enough acetabular remodelling time (up

Treatment Algorythm
For DDH treatment

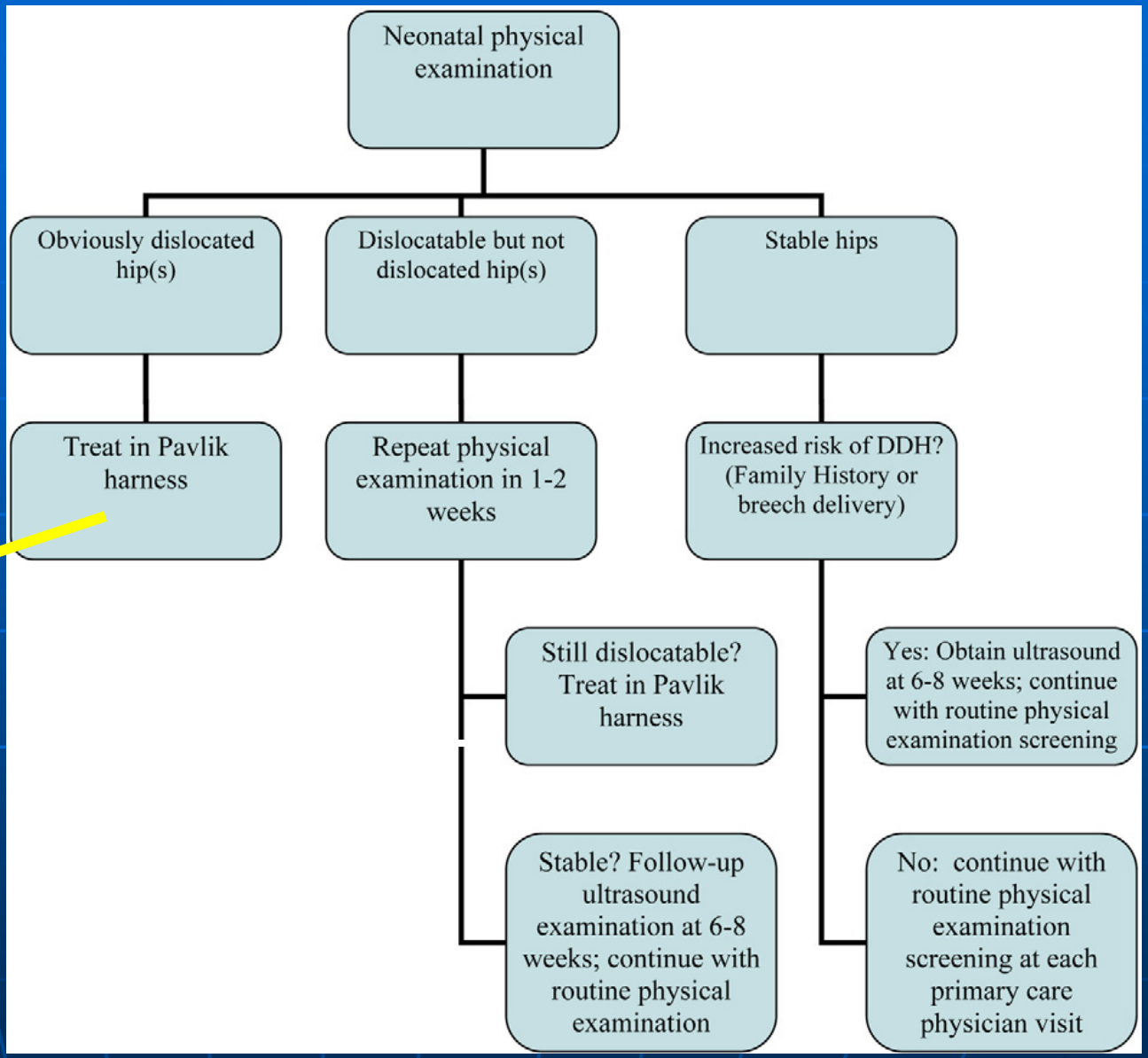

Confirm reduction within 2-3 weeks to continue this form of treatment

Modified from:
JBJS 91-A (7) JULY 2009, pg 1707

Take home Points

- Good consistent examination key to management of DDH
- Little role for Ultrasound as screening tool in first 6 weeks of life
  - Treatment often dictated by examination alone
- Early Ultrasound plays key role in assessing EFFICACY of treatment
  - confirming hip in joint with Pavlik treatment
- Early use in NORMAL EXAM babies unwarrented (less than 6 weeks)
  - “Positives” likely to be “false positives” and would need another study after 6 weeks of age
  - Negatives are reassuring but this resource is too valuable to waste “just in case”

Take home points

- DDH screening after 6 months of age is generally with plain radiography alone
  - Continues as such for life
- Typical examination for instability unreliable after 4-6 months of age
    - decreased abduction most sensitive sign for dislocation
    - Subtle dysplasia asymptomatic until arthritis decades later
- Often subtle dysplasia problematic in guiding treatment
  - Surgeon dependant (over/under treaters)
  - Discussion with parents ($ costs, expected course)

Questions or Comments?

Video-conferencers:
Unmute your system to ask a question

Webcasters:
Type your question

Thank you!

(Quyanainni) (Quana) (Ma'na)
(Qujannamiik) (Nakurmiik)

for participating in today's

Pediatric Telehealth Rounds

Join us next time:

Bronchiolitis

With Dr. Sample

Jan 23, 2015

CHEO

pedtelehealthrounds@cheo.on.ca